

## Diagnosis and Treatment of Syndesmotic Unstable Injuries: Where We Are Now and Where We Are Headed

Lorena Bejarano-Pineda, MD 

Christopher W. DiGiovanni, MD

Gregory R. Waryasz, MD

Daniel Guss, MD, MBA

### ABSTRACT

Up to 10% of ankle sprains are considered “high ankle” sprains with associated syndesmotic injury. Initial diagnosis of syndesmotic injury is based on physical examination, but further evaluation of the distal tibiofibular joint in the sagittal, coronal, and rotational planes is necessary to determine instability. Imaging modalities including weight-bearing CT and ultrasonography allow a physiologic and dynamic assessment of the syndesmosis. These modalities in turn provide the clinician useful information in two and three dimensions to identify and consequently treat syndesmotic instability, especially when subtle. Because there is notable variability in the shape of the incisura between individuals, contralateral comparison with the uninjured ankle as an optimal internal control is advised. Once syndesmotic instability is identified, surgical treatment is recommended. Several fixation methods have been described, but the foremost aspect is to achieve an anatomic reduction. Identifying any associated injuries and characteristics of the syndesmotic instability will lead to the appropriate treatment that restores the anatomy and stability of the distal tibiofibular joint.

From the Foot & Ankle Research and Innovation Laboratory (Bejarano-Pineda, DiGiovanni, Waryasz, and Guss), Harvard Medical School, Massachusetts General Hospital; Foot & Ankle Service (Bejarano-Pineda, DiGiovanni, Waryasz, and Guss), Department of Orthopaedic Surgery, Massachusetts General Hospital; Newton-Wellesley Hospital (Bejarano-Pineda, DiGiovanni, Waryasz, and Guss), Harvard Medical School, Massachusetts General Hospital, Boston.

None of the following authors or any immediate family member has received anything of value from or has stock or stock options held in a commercial company or institution related directly or indirectly to the subject of this article: Bejarano-Pineda, DiGiovanni, Waryasz, and Guss.

*J Am Acad Orthop Surg* 2021;29:985-997

DOI: 10.5435/JAAOS-D-20-01350

Copyright 2021 by the American Academy of Orthopaedic Surgeons.

**A**nkle sprains represent up to 30% of all sports-related injuries,<sup>1</sup> and up to 10% of such sprains are considered “high ankle” sprains with associated syndesmotic injury.<sup>2</sup> Although the incidence of syndesmotic injury is frequently intermixed within the overall incidence of ankle sprains, an estimated of 2.09 syndesmotic injuries per 100,000 person-years occur. High ankle sprains result in greater time lost to play compared with lateral ankle sprains, averaging 13.9 versus 8.1 days.<sup>1,3</sup> Mauntel et al<sup>4</sup> reported more than 7 days of participation restriction of 47.1% college athletes with high ankle sprains over a 5-year period.

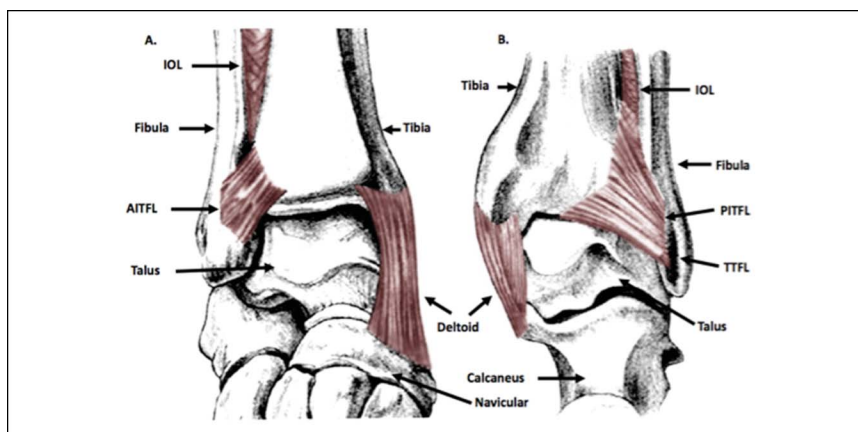
**Figure 1**

Illustration of the anterior (A) and posterior (B) views of the ankle joint demonstrating the osseous and ligamentous anatomy of the distal tibiofibular joint. AITFL = anterior inferior tibiofibular ligament, IOL = interosseous ligament, PITFL = posterior inferior tibiofibular ligament, TTFL = transverse tibiofibular

## Anatomy

An intact, functional syndesmosis is critical in ensuring stability of the ankle mortise, and the integrity of the distal tibiofibular relationship is largely maintained by ligamentous rather than bony anatomy. The incisura fibularis tibiae is a concave groove in the distal tibia formed by the anterior (Chaput's) tubercle and posterior (Volkman's) tubercles. Although a deep incisura may constrain sagittal plane translation of the distal fibula, its depth is variable and may be convex in 16% of patients.<sup>5</sup> Thus, ligamentous structures including the anterior inferior tibiofibular ligament (AITFL), interosseous ligament (IOL), and posterior inferior tibiofibular ligament (PITFL) are essential toward maintaining these distal tibiofibular relationships (Figure 1). The AITFL primarily limits external rotation of the fibula, and biomechanical studies suggest that isolated injuries to the AITFL result in approximately 24% reduction of resistance to external rotation.<sup>6</sup> The IOL prevents coronal plane translation of the fibula, especially during ankle dorsiflexion. Finally, the PITFL extends from the posterior tibial tubercle to the fibula and limits posterior translation of the fibula. The PITFL is the strongest ligament according to several biomechanical studies, potentially explaining its propensity to avulse the posterior malleolus rather than rupture.<sup>7</sup>

## Classification

Although several classification systems attempt to grade the severity of syndesmotic injury, none distinguish between stable and unstable injuries, unless there is overt

radiographic widening of the mortise (Table 1). The clinical utility of classification systems remains limited, especially in the “middle grades” as instability becomes more subtle. Syndesmotic injuries can also be classified based on chronicity. Van den Bekerom et al<sup>8</sup> defined acute injuries as less than 6 weeks, subacute injuries as greater than 6 weeks and less than 6 months after injury, and chronic injuries as those diagnosed beyond 6 months. Porter<sup>9</sup> considered syndesmotic injuries as acute if the diagnosis was made less than 4 weeks and chronic when the duration of symptoms exceeded 3 months. In turn, the Ankle and Foot Associates section of the European Society for Sports Traumatology, Knee Surgery and Arthroscopy (ESSKA-AFAS) consensus classified syndesmotic injuries as (1) acute when <6 weeks; (2) subacute between 6 weeks and 6 months; and (3) chronic when >6 months.<sup>10</sup>

## Diagnostic Techniques

### Clinical Examination

Initial diagnosis of syndesmotic injury is based on physical examination. Clinical findings include pain over the anterior and posterior distal tibiofibular articulation radiating above the leg and ankle joint that worsens with weight bearing or stress of the joint. Sman et al<sup>11</sup> found that tenderness to palpation over the syndesmotic ligaments had the highest sensitivity (92%), as the squeeze test had the highest specificity (88%) to diagnose syndesmotic injuries. The height of the zone of injury, defined as the height of tibiofibular tenderness relative to the tip of the fibula, serves as a notable predictor of time to return to unrestricted

**Table 1. Classification Systems for Syndesmotic Injury**

Classification System	Description
West Point Ankle	Grade I: Positive squeeze or external rotation test with no mortise widening radiographically Grade II: Positive squeeze and external rotation test with no mortise widening radiographically Grade III: Signs and symptoms of grade II injury with mortise widening radiographically
Porter	Grade I: Injury of the AITFL, IOL, and anterior deltoid ligament Grade II: Injury of a significant portion of the syndesmosis and disruption of the anterior and deep deltoid ligament Grade III: Complete disruption of the syndesmosis and the entire deltoid ligament
Kelikian and Kelikian	Type I: Rupture of the anterior components of the syndesmosis Type II: Disruption of all syndesmotic ligaments with associated rupture of the deltoid ligament or fracture of the medial malleolus Type III: Rupture of the interosseous membrane combined with a fibular fracture and a physeal fracture of the tibia, without lesion of the syndesmotic ligaments
Marymont	Grade 0: No widening, negative bone scintigraphy Grade 1: No widening, positive bone scintigraphy Grade 2: Widening of the ankle mortise radiographically <1 mm Grade 3: Widening of the ankle mortise radiographically >1 mm
Sikka	Grade I: Isolated injury of the AITFL Grade II: Injury of the AITFL, IOL, and interosseous membrane Grade III: Injury of the AITFL, IOL, interosseous membrane, and PITFL Grade IV: Disruption of all syndesmotic ligaments associated with the rupture of the deltoid ligament

AITFL = anterior inferior tibiofibular ligament, IOL = interosseous ligament, PITFL = posterior inferior tibiofibular ligament

activity after high ankle sprains. Clinical findings are critical for diagnosis and elucidating instability. Several stress tests have been described to evaluate the syndesmosis during clinical examination; however, their utility in the literature has generally been correlated with injury rather than confirmed instability (Table 2). Currently, the evidence does not support any single test to decisively diagnose syndesmotic instability. Pronation-external rotation- and pronation-abduction-type ankle fractures in the Lauge-Hansen classification system are commonly associated with syndesmotic injuries.<sup>12</sup> Proximal fibular fractures (Maisonneuve) and about 20% of supination-external rotation-type injuries have also been associated with syndesmotic instability.<sup>13</sup> Pure ligamentous syndesmotic injuries can be missed specifically when there is no frank diastasis. Therefore, a detailed history and physical examination is considered a mandatory component of establishing the correct diagnosis and treatment.

### Radiographs

Initial radiographic evaluation should include weight-bearing views (AP, lateral, and mortise) of the ankle to

assess the bony alignment and any associated fractures. Suggested normal radiographic parameters include a tibiofibular clear space of <6 mm on AP and mortise views, a medial clear space overlap equal to the superior clear space but not greater than 4 mm, and a tibiofibular overlap of >6 mm on AP or >1 mm on mortise views (Figure 2). Some have in turn narrowed these parameters to include a value of 5.3 mm for the tibiofibular clear space and 2.8 mm for the medial clear space among patients with ligamentous injury. Given the variability in the shape of the incisura between individuals, absolute values such as tibiofibular clear space may have limited utility.<sup>14</sup> Clinicians should have a low threshold for attaining contralateral comparison views of the uninjured ankle as the optimized, evidence-based, internal control.

Stress radiographs for latent syndesmotic instability have been described but suffer from poor reproducibility. Lui et al<sup>15</sup> compared intraoperative stress radiographs and ankle arthroscopy to assess syndesmotic disruption associated with ankle fractures, detecting only 45% of cases of latent syndesmotic instability compared with arthroscopic evaluation. Although the use of plain radiographs remains a part of the evaluation, their low

**Table 2.** Described Diagnostic Tests to Assess Syndesmotic Injury

Diagnostic Test	Description	Sensitivity	Specificity
Squeeze test	The patient is sitting with the knee flexed at 90°. Medial/lateral compression force is applied between the fibula and the tibia above the midpoint of the calf using one or both hands. Pain in the syndesmotic area indicates a positive test.	26%-100% <sup>11,46</sup>	63%-88% <sup>11,46</sup>
External rotation test	Patient is seated. Passive external rotation stress is applied to the affected foot and ankle with the knee at 90° and ankle in neutral or dorsiflexion. Pain over the anterior area of the syndesmosis indicates a positive test.	50%-71% <sup>11</sup>	63% <sup>11</sup>
Cotton test	The talus is translated from medial to lateral within the mortise. Increased translation compared with the contralateral side or pain indicates a positive test.	29% <sup>47</sup>	71% <sup>47</sup>
Fibular translation test	Apply AP translation of the fibula. AP displacement of the fibula greater than the contralateral side indicates a positive test.	64% <sup>47</sup>	57% <sup>47</sup>
Single-leg hop	The patient tries to do a single-leg hop from the toes; the inability to hop indicates a positive test for syndesmotic injury.	89% <sup>11</sup>	29% <sup>11</sup>
Cross-leg test	The patient places the injured leg across the kneecap of the opposite leg, with the pivot point at the junction of the middle and distal thirds of the tibia. If applying gentle force on the medial knee produces pain, it indicates a positive test.	N/A	N/A
Stabilization test	Stabilizing tape is applied tightly above the ankle joint and the patient should stand, walk, and perform a toe raise and jump. If these maneuvers produce less pain after taping compared to before taping, the test is considered positive.	N/A	N/A

sensitivity in diagnosing syndesmotic instability has spurred the use of additional imaging modalities.

### Ultrasonography

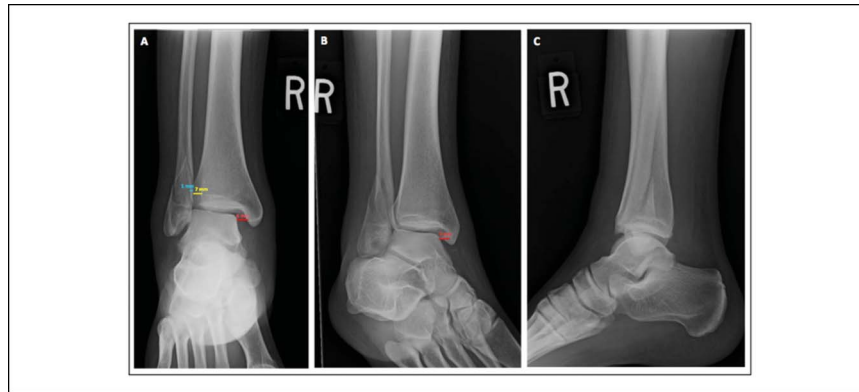
Ultrasonography offers the advantages of dynamic, noninvasive imaging at a lower cost and at the point of care. A high-frequency transducer (at least 10 MHz) is recommended for ankle joint assessment, but the external anatomy of the ankle requires a smaller probe than that used for abdominal or obstetric evaluation.<sup>16</sup> Integrity of the AITFL, IOL, PITFL, interosseous membrane, and the tibiofibular clear space can all be evaluated with ultrasonography (Figure 3). Fisher et al<sup>16</sup> performed a dynamic external rotation stress evaluation of the syndesmosis in supination-external rotation ankle injuries. They concluded that a tibiofibular clear space

widening of 6 mm or greater is diagnostic for syndesmotic injury. Hagemeyer et al<sup>17</sup> recently described excellent intraobserver and interobserver agreement (>0.8) in dynamic stress ultrasonography evaluation of the syndesmosis. These findings make the test a reliable and accessible option for the diagnosis of syndesmotic injury, especially in patients with contraindications to MRI.

### CT

Syndesmotic instability is a multiplanar condition affecting the distal tibiofibular joint in the coronal, sagittal, and rotational planes. CT scan is a diagnostic tool that affords two- and three-dimensional (3D) evaluation of the syndesmosis. Several measurement methods have been described to assess the integrity of the syndesmosis on CT scan (Table 3). Abdelaziz et al<sup>18</sup> reported a high

**Figure 2**

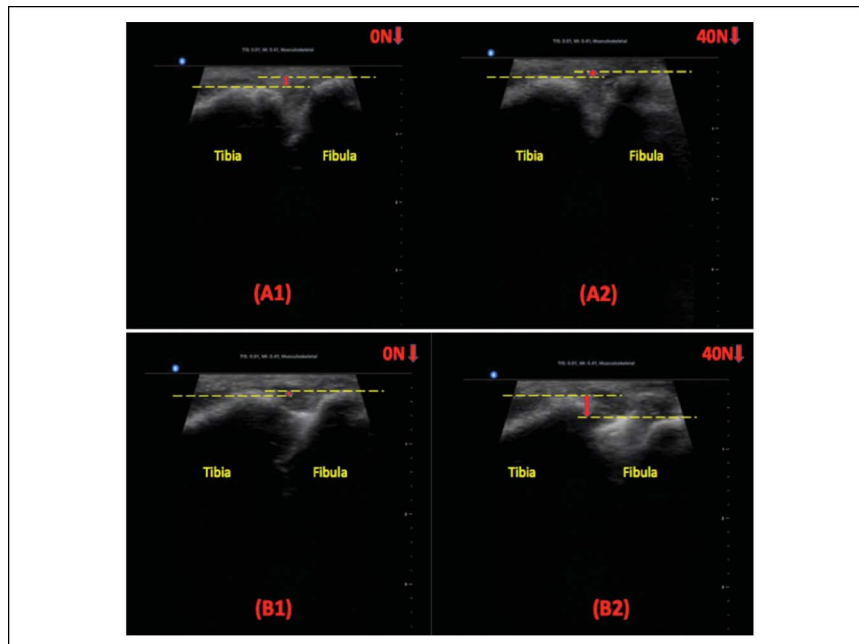


Plain radiographs of the ankle of a 25-year-old man with syndesmotic instability associated with equivalent bimalleolar ankle fracture. AP view (A) shows a tibiofibular clear space (yellow line) and tibiofibular overlap (blue line) of 7 and 1 mm, respectively. The AP and mortise (B) views show a medial clear space greater than 4 mm (red line). Lateral view (C).

interobserver (0.96) and intraobserver (>0.92) reliability of the syndesmotic area calculation in patients with unstable syndesmotic injuries. Given the substantial anatomical variability of the distal tibiofibular relationship and incisura shape among individuals, several authors have recommended bilateral CT as an internal control.<sup>19,20</sup> Weight-bearing CT (WBCT) is a relatively new diagnostic tool that provides an evaluation of the distal tibiofibular relationship under the physiologic load,

potentially expanding its diagnostic utility in syndesmotic instability (Figure 4).<sup>21</sup> Del Rio et al<sup>22</sup> compared the findings of non-weight-bearing CT versus WBCT among patients with unstable syndesmoses. They found a dynamic change in the syndesmotic area of 13.7% on WBCT compared with non-weight-bearing CT. Additional studies by Bhimani et al<sup>23</sup> have further suggested the role of volumetric measurements in identifying syndesmotic instability. They found the volumetric

**Figure 3**



Ultrasonography images of the ankle in an intact stage under 0 N of force (A1) and under 40 N of force (A2) during the fibular translation test posteriorly. Likewise, ultrasonography images of the ankle after injury to AITFL + IOL + PITFL under 0 N of force (B1) and under 40 N of force (B2) during the fibular translation test posteriorly. AITFL = anterior inferior tibiofibular ligament, IOL = interosseous ligament, PITFL = posterior inferior tibiofibular ligament

**Table 3.** Description of Measurement Methods in CT for Syndesmotic Injury

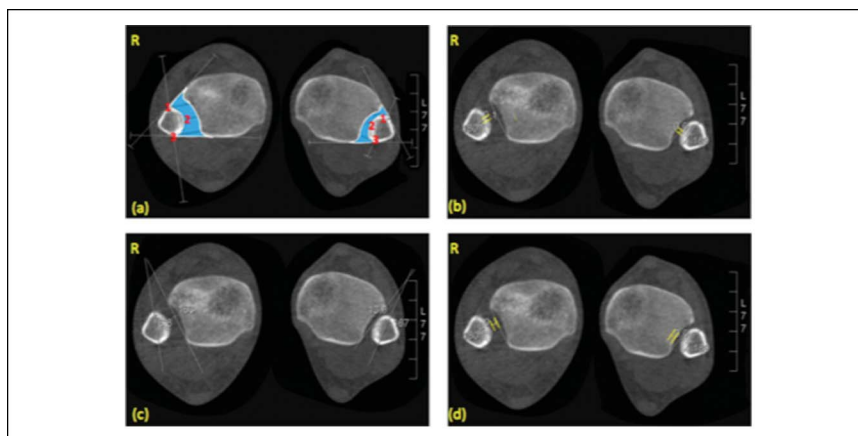
Method	Description
Anterior tibiofibular tangential angle	The angle between the tangent to the anterior tibial surface at its most anterior point and the bisection of the vertical midline of the fibula.
Tibiofibular line	A straight line placed along the anterolateral cortex of the fibula extending anteromedially to cross the tibia. The distance from the line to the anterior tubercle of the tibia determines syndesmotic instability. Normal value $\leq 2\text{mm}$ .
Fibular translation	The distance between a line representing the direct anterior difference and the anterior border of the tibial incisura. It is positive when the fibula is posterior to the anterior border of the incisura.
Syndesmotic area	The space between the lateral cortex of the tibial incisura, the medial cortex of the lateral malleolus, and 2 lines tangential to the anterior and posterior aspects of the tibia and fibula. A difference of $>45\text{ mm}^2$ compared to the contralateral ankle suggests syndesmotic instability.
Syndesmotic volume	Defined as the syndesmotic area spanning from the joint line to 5 cm proximally. An absolute volume of $>14$ or $>6\text{ cm}^3$ compared to the contralateral ankle suggests syndesmotic instability.
Fibular rotation	Angle between a line drawn between the anterior and posterior borders of the incisura and a line drawn in the fibula representing its orientation. The angle is positive when the fibula is internally rotated relative to the incisura.

measurement spanning from the tibial plafond to 5 cm proximally to be the most sensitive measurement to determine syndesmotic instability. They also described a difference of  $5.9\text{ cm}^3$  between the injured ankle and the contralateral side (Figure 5). As with radiographs, the wide variation in syndesmotic measurements between

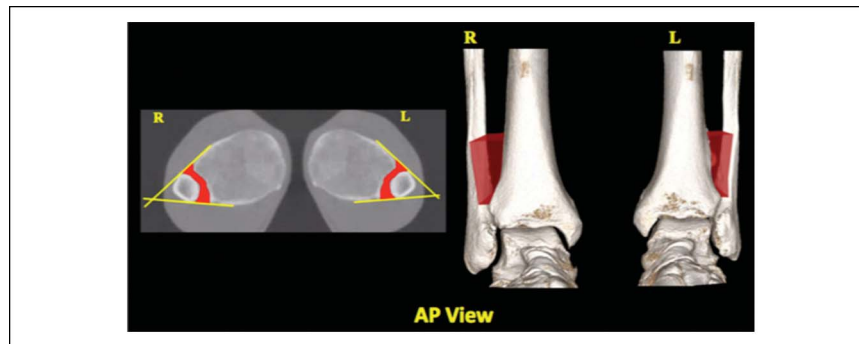
individual patients underscores the importance of using the contralateral side as an internal control.

### MRI

MRI effectively diagnoses syndesmotic injury with a high degree of sensitivity and specificity,<sup>24</sup> and given its

**Figure 4**

WBCT images of the (A) syndesmotic area (blue); direct anterior (1), middle (2), and direct posterior (3) difference; (B) sagittal translation; (C) fibular rotation, and (D) depth of the incisura. The patient had right-sided syndesmotic instability after an acute posterolateral ankle dislocation. R = right side, WBCT = weight-bearing CT

**Figure 5**

Syndesmotic volume using WBCT: A 25-year-old patient with right syndesmotic injury; volume up to 5 cm from the tibial plafond right 16.2 cm<sup>3</sup> versus left 10.1 cm<sup>3</sup>. L = left side, R = right side, WBCT = weight-bearing CT

nature of being a nondynamic test without the physiologic load, it effectively diagnoses injury but not instability. Its ability to determine the need for surgical stabilization is therefore limited, and its overall utility often relates to its ability to evaluate other intra-articular and periarticular pathology that may need to be addressed at the time of surgery.

### Diagnostic Arthroscopy

Arthroscopic assessment of the syndesmosis has become a useful technique to evaluate subtle or chronic instability of the syndesmosis (Figure 6). Diagnostic arthroscopy is currently considered the benchmark for diagnosing syndesmotic instability given that it allows direct visualization of the distal tibiofibular joint, although the absolute parameters by which this determination is made arthroscopically remain a matter of ongoing debate. In a cadaver model, Lubberts et al<sup>25</sup> described the degree of ligamentous injury necessary to precipitate sagittal plane instability. They found that the AITFL, IOL, and PITFL must be injured to generate excessive sagittal fibular motion, averaging 2 mm of total translation. In turn, Massri-Pugin et al<sup>26</sup> similarly examined the amount of syndesmotic injury necessary to precipitate tibiofibular diastasis in the coronal plane. They found that although the syndesmotic instability occurs with injury to the AITFL, IOL, and PITFL, partial injuries to the syndesmosis involving only the AITFL and IOL can also render the distal tibiofibular joint unstable if the deltoid is concomitantly injured. They noted that such diastasis is best measured at the posterior third of the incisura. Likewise, Lubberts et al<sup>27</sup> highlighted the need to remove the ankle from distraction when evaluating the distal syndesmosis arthroscopically because of its propensity to mask subtle instability. Other biomechanical studies have high-

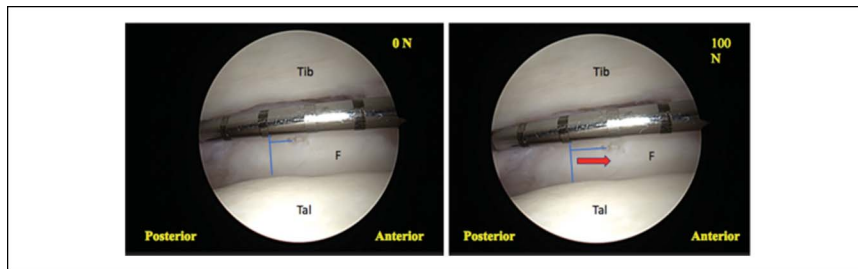
lighted that fibular translation in the sagittal plane may be more sensitive (78%) and specific (89%) to establish instability that assessed in the coronal plane. Coronal plane instability is assessed performing the Cotton test. A diastasis of >3 mm suggests syndesmotic instability.<sup>30</sup> Likewise, sagittal instability is assessed applying a force to the fibula in both an anterior to posterior and a posterior to anterior direction. Fibular motion >2 mm suggests syndesmotic instability.<sup>31</sup>

We recommend diagnostic arthroscopy for the evaluation of syndesmotic instability when a clinical history and physical examination are persistently suggestive of instability, when noninvasive diagnostic modalities are inconclusive, and when other elements of the differential diagnosis are ruled out in a patient who continues to generate symptoms that prevent return to the preinjury level of function (Figure 7).

### Where Are We Heading in the Future Regarding Diagnostic Techniques?

Effective evaluation of the distal tibiofibular articulation must take into account that syndesmotic instability occurs along a continuum of severity and within three separate planes and that such instability, when subtle, may only become visible under stress or the physiologic load. Therefore, additional imaging modalities beyond radiographs are necessary in the absence of frank diastasis. Arthroscopy is the benchmark for the evaluation of the distal tibiofibular joint, allowing evaluation of the syndesmosis while applying a stress. However, its invasive nature, cost, and inability to afford a contralateral comparison also limit its use to patients with a high index of preoperative suspicion. Weight-bearing CT has overcome many of these limitations, affording multiplanar evaluation under physiologic loads. Its application

**Figure 6**

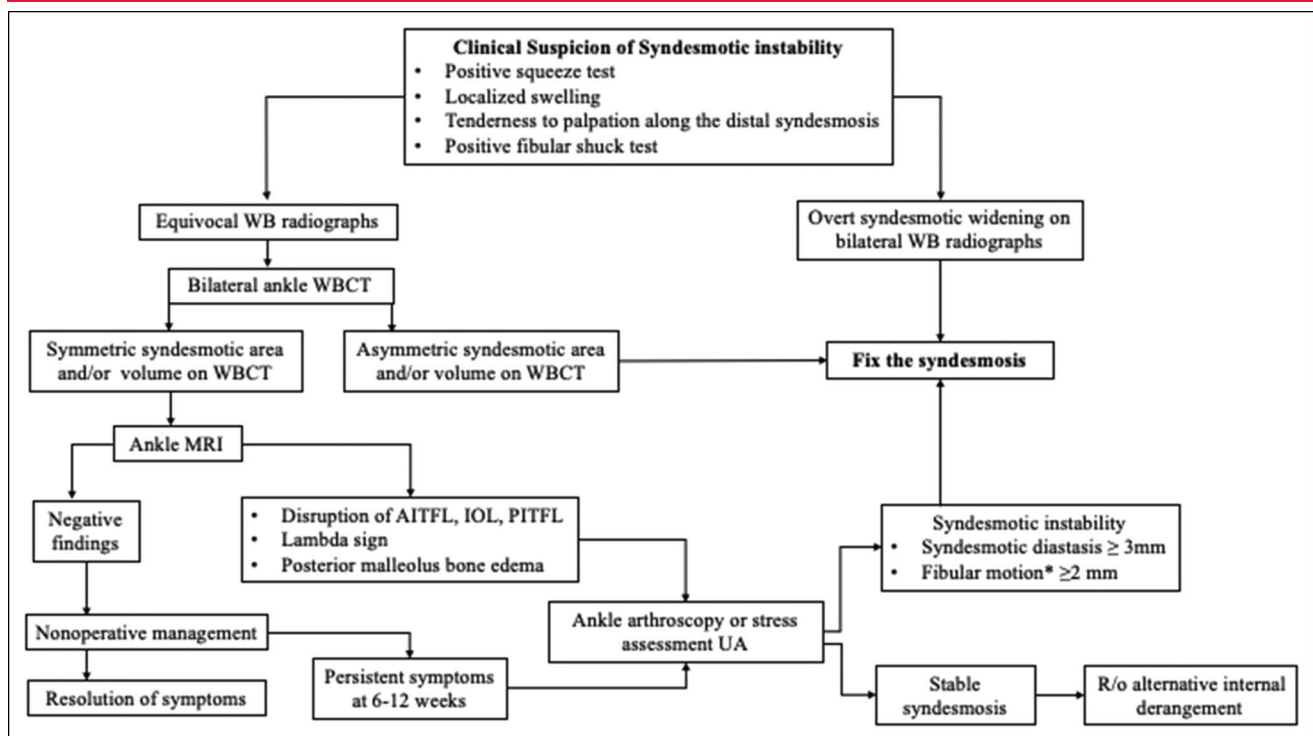


Arthroscopic posterior to anterior sagittal translation after AITFL and ATFL injury at 0 and 100 N force. Arrow indicates the direction of pull from posterior to anterior direction with hook. AITFL = anterior inferior tibiofibular ligament, ATFL = anterior talofibular ligament, F = fibula, Tal = talus, Tib = tibia

has continued to evolve, and earlier one-dimensional measurements have already been superseded by two-dimensional and even 3D measurements at the distal tibiofibular articulation using the contralateral side as an internal control. Volume measurements may be especially suited to identifying increasingly subtle instability and in the future are likely to become integrated into viewing programs in a manner that is accessible to clinicians beyond just the research realm. Ultrasonography has also begun to play an increasing role in this evaluative process and may become the alternative diagnostic

benchmark given its noninvasive, nonradiation, low cost, readily available nature at the point of care; moreover, ultrasonography also has the ability to evaluate the distal tibiofibular relationship under stress while using the contralateral side as an internal control. Ultimately, having a firm understanding of syndesmotomc anatomy and biomechanics while armed with an array of imaging modalities, clinicians in the future may be better equipped to diagnose and treat syndesmotomc instability, especially when subtle.

**Figure 7**



Diagnostic algorithm for syndesmotomc instability: \*Fibular motion in the sagittal plane. AITFL = anterior inferior tibiofibular ligament, IOL = interosseous ligament, PITFL = posterior inferior tibiofibular ligament, UA = under anesthesia, WB = weight bearing, WBCT = weight-bearing CT



## Surgical Management of Syndesmotic Instability

### Acute Injuries

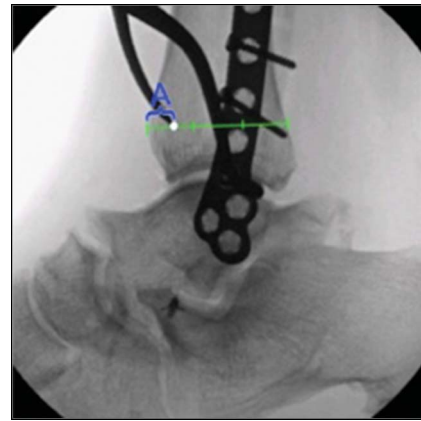
Given the long-term and often irreversible morbidity associated with untreated syndesmotic instability, strong consideration should always be given to surgical stabilization whenever instability is identified at the distal tibiofibular articulation. The fundamental goal of surgical treatment is to achieve anatomic reduction of the fibula within the incisura and to stabilize the articulation that remains sustainable over time. Important considerations to reach this goal are (1) timely reduction and stabilization of the syndesmosis; (2) treatment of any associated pathology; and (3) comprehensive rehabilitation. Among syndesmotic injuries with associated ankle fractures, it is critical that the fibula be anatomically reduced with a special attention paid to maintaining the fibular length.<sup>2</sup> In contradistinction, Maisonneuve injuries with associated proximal fibular fractures generally do not require surgical repair of the fibular fracture site itself whenever fibular length and rotation can be properly restored distally. In such scenarios, surgeons can often focus primarily on the distal tibiofibular articulation itself. Although we consider it is not ideal, if the treating surgeon has a minor suspicion of instability after performing all the recommended diagnostic tests, we consider it is less harmful for the patient to be overtreated than undertreated.

### Reduction Technique

Biomechanical studies have underscored that syndesmotic instability is 3D in nature. Historic focus has often been on the coronal plane; nevertheless, arthroscopic studies have strongly suggested that sagittal plane instability can exceed what occurs in the coronal plane and must be considered when surgically repairing an unstable syndesmosis.<sup>31</sup> Malreduction in the sagittal plane has been attributed to technical factors such as incorrect periarticular reduction clamp placement, mispositioning of syndesmotic implant, or failure to repair a sizeable posterior malleolar fracture.

Reduction of the distal tibiofibular articulation using a pointed reduction forceps is a commonly described method to realign an unstable syndesmosis. There continues to be controversy whether this technique should be used in the treatment of syndesmotic injuries. Placement of the medial tine has been shown to have a wide variability and an effect on the fibular position relative to the incisura and may also potentiate overcompression of the syndesmosis.<sup>32</sup> The concept of overcompression is

**Figure 8**



Lateral view using fluoroscopy showing the placement of the medial clamp tine (white dot) and its distance from the anterior tibial cortex (distance A). Medial clamp tine is located on the anterior third of the AP width of the tibia (green line). Image adapted from Cosgrove CT, Putnam SM, Cherney SM, et al: Medial clamp tine positioning affects ankle syndesmosis malreduction. *J Orthop Trauma* 2017;31:440-446.

controversial as well, wherein it is unclear whether the interspace at the distal tibiofibular is getting over-squeezed or whether the fibula is translating posteriorly and medially on the distal tibial cross section. Likewise, the effect is unclear whether overcompression risks clinical consequence to the same extent as under-reduction or a residually unstable syndesmosis.

In a biomechanical study, Miller et al<sup>33</sup> showed that clamp placement at the medial tine can affect the orientation of the fibula during reduction and concluded that the clamp should be angled toward 0° rather than 15° or 30° to cause the least translation. Clinical studies, however, have shown different results. Cosgrove et al<sup>32</sup> demonstrated that sagittal plane malreduction appeared to be highly sensitive to clamp obliquity and recommended placing the medial clamp tine in the anterior third of the tibial line to minimize malreduction risk (Figure 8). The type of reduction forceps has also shown to have an effect on overcompression, with the pelvic ball-spike reduction clamp generating more compression compared with Weber pointed reduction forceps. The clamp used should be large enough to reach the desired points on the tibia and fibula without impinging on any of the soft tissues because this may lead to misplacement of the tines in a suboptimal position. Ultimately, the variability in these recommendations may reflect variability of in vivo fibular displacement relative to the incisura—not all syndesmotic instability is the same. If the fibula displaces directly laterally, then

central placement of the medial tine is desirable. On the other hand, if the fibula translates markedly posteriorly, then a more anterior placement of the medial tine and even a rotational reduction maneuver may be necessary to recreate normal anatomy. Reduction of the fibula is a crucial point when performing syndesmotic reduction in the setting of an associated fracture. Although the type of syndesmotic implant and the nature of syndesmotic reduction remain matters of ongoing debate, under this circumstance such patients, regardless of those decisions, are likely to end up well served by first anatomically reducing an associated distal fibular fracture and thereafter deciding to stabilize an unstable distal tibiofibular articulation.

### Rigid Fixation

Traditionally, syndesmotic screw fixation has been the technique of choice to stabilize the syndesmosis. Extensive research has been performed on the technical aspects of screw fixation, but a lack of consensus exists regarding screw size, number of cortices incorporated, location of fixation, and the need for implant removal. Classical Arbeitsgemeinschaft für Osteosynthesefragen recommendations include positioning the screw 25° to 30° to the coronal plane at least 1 cm above the ankle joint.<sup>34</sup> By contrast, Verim et al<sup>35</sup> found that the yield stress was lowest when the screw was placed at 3 to 4 cm above the tibiotalar joint.

Biomechanical studies comparing 3.5 and 4.5 mm screws found that although 4.5 mm afford greater resistance to breakage, this may not translate into a clinical benefit,<sup>36</sup> and a lack of consensus exists regarding screw size. Likewise, the literature has demonstrated no notable effect on mechanical stability between screws crossing three or four cortices. Perhaps because the tibial metaphyseal cortex is so thin, adding the medial cortex to the construct adds little mechanical advantage. Whether syndesmotic screw removal affords any clinical advantage remains debatable. Some authors have argued that removing the screw restores the normal function of the ankle joint at 8 to 12 weeks postoperatively even in cases of malreduction.<sup>37</sup> By contrast, several studies do not support routine removal of syndesmotic screws, suggesting similar outcomes while needlessly adding additional surgical burden.<sup>38</sup> Briceno et al<sup>39</sup> compared ankle dorsiflexion before and after syndesmotic screw removal and found no difference in ankle motion. In summary, although screws can arguably be criticized for causing supraphysiologic stiffness as varying potential degrees of rigid malreduction,

outcomes may appear to be optimal that if the bony anatomy has been restored then these things may not matter because (1) this stiffness facilitates excellent syndesmotic ligament scarring in an anatomic or near anatomic normalized resting length, (2) eventual implant removal or breakage often enables the fibula to “find its home” anyway, and (3) in contradistinction to recurrent or persistent syndesmotic instability patients who almost always require further surgery, “over-reduced” or “stiff” postfixation syndesmosis patients with an anatomically restored fibula rarely require return to an operating room.

### Dynamic Fixation

Suture button fixation is an alternative to syndesmotic screws that allow micromotion at the distal tibiofibular articulation while obviating any consideration of subsequent implant removal. Although clinical studies have not demonstrated the benefit of one fixation method over another, biomechanical studies have revealed both advantages and disadvantages to each. Clanton et al compared three different methods of syndesmotic fixation, including (1) syndesmotic screw; (2) one suture-button construct; and (3) two divergent suture-button constructs. They found that a single suture-button fixation afforded notably less constraint of sagittal plane fibular motion compared to the intact state, but that all constructs afforded an analogous degree of rotational control of the fibula.<sup>40</sup> Likewise, Lubberts et al<sup>41</sup> showed in a cadaver model that single suture-button constructs maintain coronal plane stability after a syndesmotic injury but fail to effectively constraint fibular motion in the sagittal plane and also raised doubt about the ability of this construct to effectively stabilize in the transverse (rotational) plane either. Most of the published data on clinical outcomes have used one suture-button constructs, whereas biomechanical data have suggested the need for a two-button, divergent construct. The current data, however, seem to suggest that at least two divergent suture buttons are more effective in controlling fibular motion in multiple planes but mainly in the sagittal plane compared with a single button construct. In the divergent construct, the suture buttons are directed from posterior to anterior with a 15° divergent angle between them.<sup>40</sup> Despite potential advantages in enabling some degree of physiologic motion after fixation, the largest drawback of these constructs is the persistent differential size of the holes created to insert them versus what is placed to fill them after fixation.

There remain notable degrees in freedom through these interfaces, which not only enables potentially undesirable motion in certain planes but may also cause a stress riser in the distal fibula that has been reported to result in fracture during rapid return to activity.

Screw fixation provides a more rigid construct constraining motion; however, studies have shown a high risk of malreduction. Current literature has shown favorable results at short term with the use of less rigid fixation methods, as the suture-button construct in syndesmotic injuries allowing micromotion at the distal tibiofibular joint notably lowers revision surgery and less malreduction rates. Shimozone et al<sup>43</sup> performed a meta-analysis comparing the clinical outcomes between suture button and syndesmotic screw. They showed that patients treated with suture button had a significantly higher postoperative American Orthopaedic Foot and Ankle Society score (95.3 versus 86.7,  $P < 0.001$ ), lower rate of broken implant (0.0% versus 25.4%,  $P < 0.001$ ), and joint malreduction (0.8% versus 11.5%,  $P = 0.05$ ).<sup>43</sup> These findings are clinically relevant, but further research is needed on its long-term effects in joint stability and the tibiotalar contact area.

#### Anterior Inferior Tibiofibular Ligament Augmentation

The authors had advocated the role of AITFL augmentation associated with suture-button fixation for unstable syndesmotic injuries by preventing fibular sagittal motion and external rotation. Shoji et al<sup>44</sup> compared the stability of the syndesmosis with different methods of fixation including AITFL augmentation with a suture tape. The authors showed that the tibiofibular diastasis and the fibular rotational angle are markedly increased after suture-button fixation alone but were not different compared with the intact model after suture-button fixation with AITFL augmentation.<sup>44</sup> The theoretical benefit of the AITFL augmentation technique includes restoration of syndesmotic stability to nearly its intact state while preserving motion.<sup>45</sup> This technique has been proposed to be beneficial in patients who are prone to instability as those with a shallow tibial incisura. As we continue evolving in this topic, further clinical research assessing the role of augmentation techniques and the minimal required stability to achieve successful clinical outcomes is needed.

#### Authors' Preferred Treatment

We recommend fixation with two 4.0 mm quadricortical screws or two suture buttons through a small one-third

tubular plate starting approximately 2 cm proximal to the tibiotalar joint line. Either the screws or suture buttons are placed in a divergent direction. Patients can start progressive range of motion at 2 weeks after surgery and weight bearing at 6 weeks. In cases of associated ankle fractures, the most critical step is to achieve an anatomic reduction of the fibula. Once fibular anatomy has been restored, reduction and fixation of the syndesmosis is performed in a similar fashion as for isolated injuries. In grossly unstable injuries with associated ankle fracture, severe comminution, or poor bone quality, we lean more toward screw fixation because of the rigidity of the system, which also augments fixation of the fibula fracture.

#### Summary

Syndesmotic instability continues to be common among athletes in contact sports and external rotation-type ankle fractures. Syndesmotic instability is a tridimensional injury, in which sagittal instability is more critical than coronal instability as previously understood. Evolving techniques including WBCT allow a multiplanar evaluation of the syndesmosis under the physiologic load without the superimposition of additional structures. Volumetric measurement of the syndesmosis can be very helpful, especially in cases of subtle instability in which a prompt diagnosis is crucial to provide adequate treatment and consequently achieve good outcomes. Ultrasonography also plays a role as a non-invasive technique that offers a dynamic evaluation at low cost with the ability to use the contralateral side as a control. Overall, the current availability of imaging modalities affords clinicians to be better equipped to address syndesmotic instability.

In terms of treatment, anatomic reduction ideally in the acute setting increases the likelihood of good functional outcome and decreases the risk of developing ankle arthritis long term. Given natural variabilities in syndesmotic anatomy, using the contralateral extremity is the most reliable parameter in determining the normal relationship of the distal tibiofibular joint. Dynamic fixation has demonstrated some advantages over rigid fixation while offering a more physiologic state after reduction. Nevertheless, further studies that include long-term follow-up are necessary to determine whether the benefits of a more flexible fixation outweigh the described limitations with rigid fixation.

## References

References printed in **bold type** are those published within the past 5 years.

- Waterman BR, Owens BD, Davey S, Zacchilli MA, Belmont PJ Jr: The epidemiology of ankle sprains in the United States. *J Bone Joint Surg Am* 2010;92:2279-2284.
- Switaj PJ, Mendoza M, Kadakia AR: Acute and chronic injuries to the syndesmosis. *Clin Sports Med* 2015;34:643-677.
- Lievers WB, Adamic PF: Incidence and severity of foot and ankle injuries in men's collegiate American football. *Orthop J Sports Med* 2015;3:2325967115581593.
- Mauntel TC, Wikstrom EA, Roos KG, Djoko A, Dompier TP, Kerr ZY: The epidemiology of high ankle sprains in National Collegiate Athletic Association Sports. *Am J Sports Med* 2017;45:2156-2163.**
- Taser F, Toker S, Kilincoglu V: Evaluation of morphometric characteristics of the fibular incisura on dry bones. *Joint Dis Relat Surg* 2009;20:52-58.
- Clanton TO, Williams BT, Backus JD, et al: Biomechanical analysis of the individual ligament contributions to syndesmotic stability. *Foot Ankle Int* 2017;38:66-75.**
- Wilson DJ: Injuries of the ligaments and tendons in the ankle and foot, in Vanhoenacker FM, Maas M, Gielen JL, eds: *Imaging of Orthopedic Sports Injuries*. Berlin, Heidelberg, Springer Berlin Heidelberg, 2007, pp 321-335.
- van den Bekerom MP, Raven EE: Arthrex tightrope distal tibiofibular syndesmotic stabilization. *Foot Ankle Int* 2009;30:577-578; author reply 578.
- Porter DA: Evaluation and treatment of ankle syndesmosis injuries. *Instr Course Lect* 2009;58:575-581.
- van Dijk CN, Longo UG, Loppini M, et al: Classification and diagnosis of acute isolated syndesmotic injuries: ESSKA-AFAS consensus and guidelines. *Knee Surg Sports Traumatol Arthrosc* 2016;24:1200-1216.
- Sman AD, Hiller CE, Rae K, et al: Diagnostic accuracy of clinical tests for ankle syndesmosis injury. *Br J Sports Med* 2015;49:323-329.
- Harper MC: Ankle fracture classification systems: A case for integration of the Lauge-Hansen and AO-Danis-Weber schemes. *Foot Ankle* 1992;13:404-407.
- Choi Y, Kwon SS, Chung CY, et al: Syndesmotic injuries in supination-external rotation-type ankle fractures. *J Bone Joint Surg* 2014;96:1161-1167.
- Elgafy H, Semaan HB, Blessinger B, Wassef A, Ebraheim NA: Computed tomography of normal distal tibiofibular syndesmosis. *Skeletal Radiol* 2010;39:559-564.
- Lui TH, Ip K, Chow HT: Comparison of radiologic and arthroscopic diagnoses of distal tibiofibular syndesmosis disruption in acute ankle fracture. *Arthroscopy* 2005;21:1370.
- Fisher CL, Rabbani T, Johnson K, Reeves R, Wood A: Diagnostic capability of dynamic ultrasound evaluation of supination-external rotation ankle injuries: A cadaveric study. *BMC Musculoskelet Disord* 2019;20:502.**
- Hagemeijer NC, Saengsin J, Chang SH, et al: Diagnosing syndesmotic instability with dynamic ultrasound—establishing the natural variations in normal motion. *Injury* 2020;51:2703-2709.**
- Abdelaziz ME, Hagemeijer N, Guss D, El-Hawary A, El-Mowafi H, DiGiovanni CW: Evaluation of syndesmosis reduction on CT scan. *Foot Ankle Int* 2019;40:1087-1093.**
- Hagemeijer NC, Chang SH, Abdelaziz ME, et al: Range of normal and abnormal syndesmotic measurements using weightbearing CT. *Foot Ankle Int* 2019;40:1430-1437.**
- Dikos GD, Heisler J, Choplin RH, Weber TG: Normal tibiofibular relationships at the syndesmosis on axial CT imaging. *J Orthop Trauma* 2012;26:433-438.
- Malhotra K, Welck M, Cullen N, Singh D, Goldberg AJ: The effects of weight bearing on the distal tibiofibular syndesmosis: A study comparing weight bearing-CT with conventional CT. *Foot Ankle Surg* 2019;25:511-516.**
- Del Rio A, Bewsher SM, Roshan-Zamir S, et al: Weightbearing cone-beam computed tomography of acute ankle syndesmosis injuries. *J Foot Ankle Surg* 2020;59:258-263.**
- Bhimani R, Ashkani-Esfahani S, Lubberts B, et al: Utility of volumetric measurement via weight-bearing computed tomography scan to diagnose syndesmotic instability. *Foot Ankle Int* 2020;41:859-865.**
- Clanton TO, Ho CP, Williams BT, et al: Magnetic resonance imaging characterization of individual ankle syndesmosis structures in asymptomatic and surgically treated cohorts. *Knee Surg Sports Traumatol Arthrosc* 2016;24:2089-2102.
- Lubberts B, Massri-Pugin J, Guss D, et al: Arthroscopic assessment of syndesmotic instability in the sagittal plane in a cadaveric model. *Foot Ankle Int* 2019;41:237-243.**
- Massri-Pugin J, Lubberts B, Vopat BG, Guss D, Hosseini A, DiGiovanni CW: Effect of sequential sectioning of ligaments on syndesmotic instability in the coronal plane evaluated arthroscopically. *Foot Ankle Int* 2017;38:1387-1393.**
- Lubberts B, Guss D, Vopat BG, Wolf JC, Moon DK, DiGiovanni CW: The effect of ankle distraction on arthroscopic evaluation of syndesmotic instability: A cadaveric study. *Clin Biomech* 2017;50:16-20.**
- Lubberts B, Guss D, Vopat BG, et al: The arthroscopic syndesmotic assessment tool can differentiate between stable and unstable ankle syndesmoses. *Knee Surg Sports Traumatol Arthrosc* 2018;28:193-201.**
- LaMothe JM, Baxter JR, Murphy C, Gilbert S, DeSandis B, Drakos MC: Three-dimensional analysis of fibular motion after fixation of syndesmotic injuries with a screw or suture-button construct. *Foot Ankle Int* 2016;37:1350-1356.
- Stoffel K, Wysocki D, Baddour E, Nicholls R, Yates P: Comparison of two intraoperative assessment methods for injuries to the ankle syndesmosis. A cadaveric study. *J Bone Joint Surg Am* 2009;91:2646-2652.
- Lubberts B, Massri-Pugin J, Guss D, et al: Arthroscopic assessment of syndesmotic instability in the sagittal plane in a cadaveric model. *Foot Ankle Int* 2020;41:237-243.**
- Cosgrove CT, Putnam SM, Cherney SM, et al: Medial clamp tine positioning affects ankle syndesmosis malreduction. *J Orthop Trauma* 2017;31:440-446.**
- Miller AN, Barei DP, Iaquinio JM, Ledoux WR, Beingessner DM: Iatrogenic syndesmosis malreduction via clamp and screw placement. *J Orthop Trauma* 2013;27:100-106.
- Vopat ML, Vopat BG, Lubberts B, DiGiovanni CW: Current trends in the diagnosis and management of syndesmotic injury. *Curr Rev Musculoskelet Med* 2017;10:94-103.**
- Verim O, Er MS, Altinel L, Tasgetiren S: Biomechanical evaluation of syndesmotic screw position: A finite-element analysis. *J Orthop Trauma* 2014;28:210-215.
- Thompson MC, Gesink DS: Biomechanical comparison of syndesmosis fixation with 3.5- and 4.5-millimeter stainless steel screws. *Foot Ankle Int* 2000;21:736-741.
- Amouzadeh Omrani F, Kazemian G, Salimi S: Evaluation of syndesmosis reduction after removal syndesmosis screw in ankle fracture with syndesmosis injury. *Adv Biomed Res* 2019;8:50.**

38. Gennis E, Koenig S, Rodericks D, Otlans P, Tornetta P. III: The fate of the fixed syndesmosis over time. *Foot Ankle Int* 2015;36:1202-1208.
39. Briceno J, Wusu T, Kaiser P, et al: Effect of syndesmotic implant removal on dorsiflexion. *Foot Ankle Int* 2019;40:499-505.
40. Clanton TO, Whitlow SR, Williams BT, et al: Biomechanical comparison of 3 current ankle syndesmosis repair techniques. *Foot Ankle Int* 2017;38:200-207.
41. Lubberts B, Vopat BG, Wolf JC, Longo UG, DiGiovanni CW, Guss D: Arthroscopically measured syndesmotic stability after screw vs. suture button fixation in a cadaveric model. *Injury* 2017;48:2433-2437.
42. McKenzie AC, Hesselholt KE, Larsen MS, Schmal H: A systematic review and meta-analysis on treatment of ankle fractures with syndesmotic rupture: Suture-button fixation versus cortical screw fixation. *J Foot Ankle Surg* 2019;58:946-953.
43. Shimozone Y, Hurley ET, Myerson CL, Murawski CD, Kennedy JG: Suture button versus syndesmotic screw for syndesmosis injuries: A meta-analysis of randomized controlled trials. *Am J Sports Med* 2019; 47:2764-2771.
44. Shoji H, Teramoto A, Suzuki D, et al: Suture-button fixation and anterior inferior tibiofibular ligament augmentation with suture-tape for syndesmosis injury: A biomechanical cadaveric study. *Clin Biomech* 2018;60:121-126.
45. Teramoto A, Shoji H, Sakakibara Y, et al: Inferior tibiofibular ligament augmentation using suture tape for tibiofibular syndesmosis injuries. *J foot Ankle Surg* 2018;57:159-161.
46. Nussbaum ED, Hosea TM, Sieler SD, Incremona BR, Kessler DE: Prospective evaluation of syndesmotic ankle sprains without diastasis. *Am J Sports Med* 2001;29:31-35.
47. Beumer A, Swierstra BA, Mulder PG: Clinical diagnosis of syndesmotic ankle instability: Evaluation of stress tests behind the curtains. *Acta Orthop Scand* 2002;73:667-669.