

# Etiology, Evaluation, and Management Options for the Stiff Digit

Louis W. Catalano III, MD

O. Alton Barron, MD

Steven Z. Glickel, MD

Shobhit V. Minhas, MD

From the Department of Orthopedic Surgery, NYU Langone Orthopedic Hospital, New York, NY.

Dr. Catalano or an immediate family member serves as a paid consultant to Smith and Nephew. Dr. Barron or an immediate family member has received IP royalties from and serves as a paid consultant to Extremity Medical and serves as a board member, owner, officer, or committee member of the American Shoulder and Elbow Surgeons and the American Society for Surgery of the Hand. Dr. Glickel or an immediate family member serves as an unpaid consultant to Acumed, LLC and serves as a board member, owner, officer, or committee member of the American Society for Surgery of the Hand. Neither Dr. Minhas nor any immediate family member has received anything of value from or has stock or stock options held in a commercial company or institution related directly or indirectly to the subject of this article.

*J Am Acad Orthop Surg* 2019;27:e676-e684

DOI: 10.5435/JAAOS-D-18-00310

Copyright 2018 by the American Academy of Orthopaedic Surgeons.

## Abstract

The stiff digit may be a consequence of trauma or surgery to the hand and fingers and can markedly affect a patient's level of function and quality of life. Stiffness and contractures may be caused by one or a combination of factors including joint, intrinsic, extensor, and flexor tendon pathology, and the patient's individual biology. A thorough understanding of the anatomy, function, and relationship of these structures on finger joint range of motion is crucial for interpreting physical examination findings and preoperative planning. For most cases, nonsurgical management is the initial step and consists of hand therapy, static and dynamic splinting, and/or serial casting, whereas surgical management is considered for those with more extensive contractures or for those that fail to improve with conservative management. Assuming no bony block to motion, surgery consists of open joint release, tenolysis of flexor and/or extensor tendons, and external fixation devices. Outcomes after treatment vary depending on the joint involved along with the severity of contracture and the patient's compliance with formal hand therapy and a home exercise program.

Digital stiffness is a common complication after trauma and surgery and can markedly impair function and quality of life of patients.<sup>1</sup> Without treatment, this may result in permanent contractures. Although the practical demands of the hand vary between individuals, the basic functions of pinch, grasp, and grip are crucial for an independent productive life.

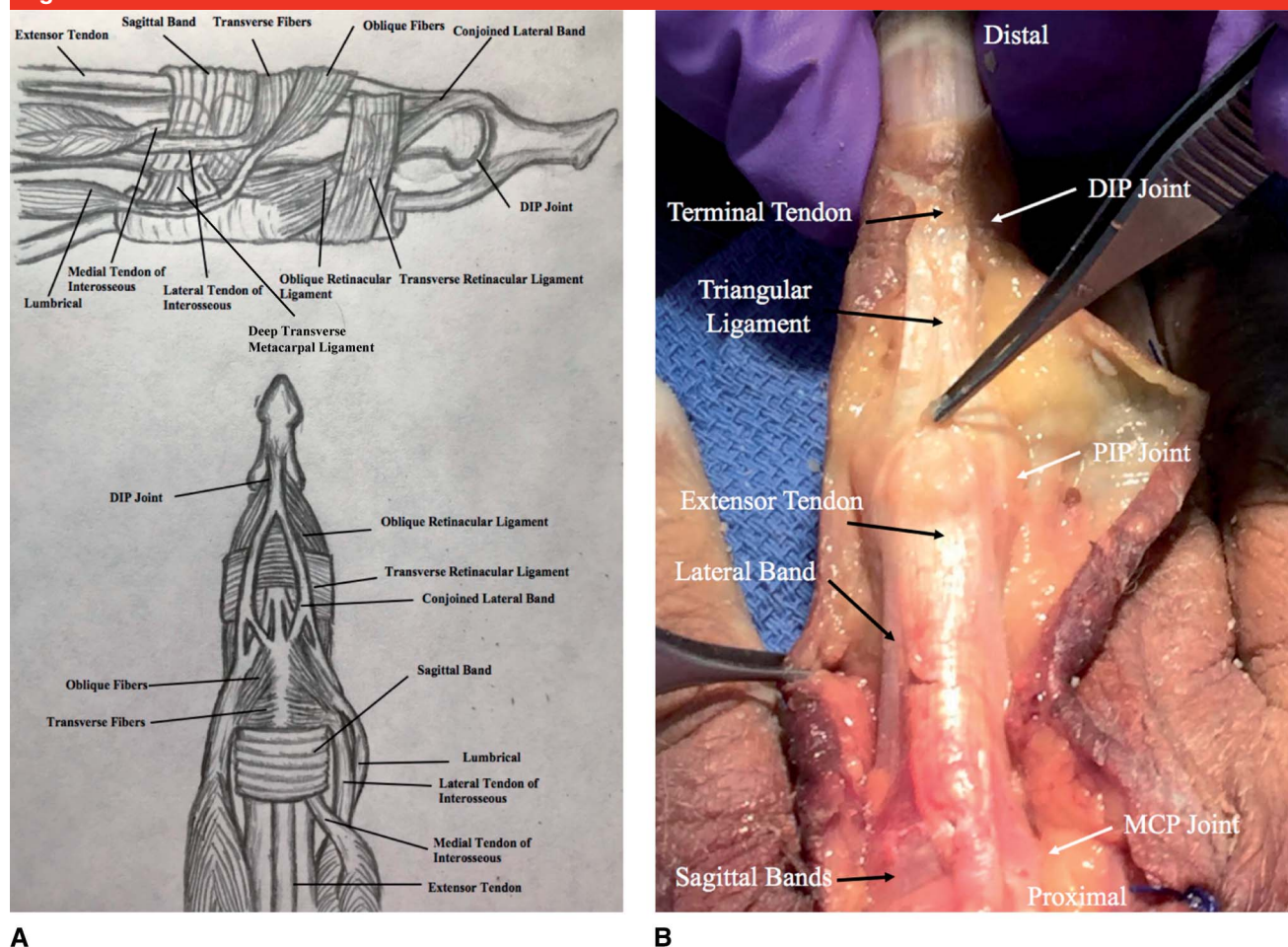
Osseous stability with a congruent articular surface, integrity and strength of the musculotendinous unit, tendon gliding, and pliable skin and soft tissues are all required for full digital range of motion (ROM). An understanding of the anatomy and pathology associated with specific contractures is imperative for effective treatment (Figures 1 and 2).

The initial management of the stiff finger includes nonsurgical modalities such as serial casting, splinting, and guided therapy to restore normal motion. Surgery is indicated for patients with persistent contracture and functional compromise. In this review, we highlight the relevant anatomy of the digit, the clinical evaluation and differential diagnosis of finger contractures, treatment options, and outcomes.

## Anatomy

### Metacarpophalangeal Joint

The metacarpophalangeal (MCP) joint is a multiaxial condyloid joint that allows for flexion, extension, abduction, adduction, and a small

**Figure 1**

**A**, Illustration of digital extensor apparatuses. **B**, Dorsal dissection of digit demonstrating extensor mechanism. DIP = distal interphalangeal, MCP = metacarpophalangeal, PIP = proximal interphalangeal

degree of circumduction. It consists of the capsule, two proper collateral ligaments, two accessory collateral ligaments, and the volar plate. The joint capsule is loose in its substance but stabilized by connective tissue on all sides, attaching to the articular rim of the metacarpal head and base of the proximal phalanx. The redundancy of the capsular tissue allows for variable hyperextension of the proximal phalanx, distraction, and a small degree of axial rotation. The volar plate limits hyperextension of the MCP joint.

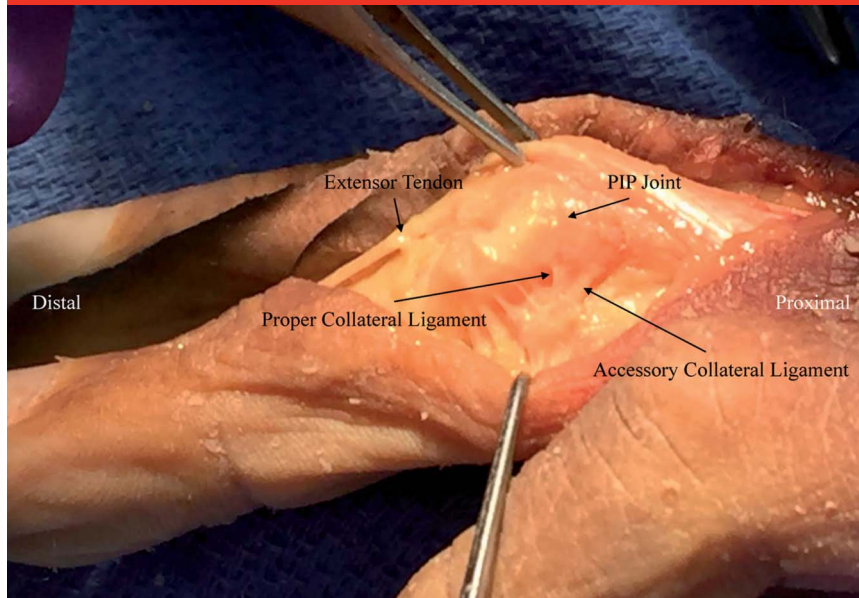
The collateral ligaments arise from the radial and ulnar subcapital area of the dorsal metacarpal head and

course toward the volar base of the proximal phalanx. The accessory ligaments originate volar to the collateral ligaments on the metacarpal head and fan out to blend with the collateral ligaments, attaching to the proximal phalanx and the volar plate. The metacarpal head is trapezoidal in shape, being wider volarly. This shape and the collateral ligaments' eccentrically dorsal origin to the axis of rotation create a cam effect as the proximal phalanx is flexed and the collaterals are stretched. Hence, MCP joint flexion tensions the collateral ligaments, creating maximum MCP joint stability.

The collateral ligaments are lax in extension (the same cam effect reversed), so MCP joints that remain extended will become stiff as the lax ligaments contract. This tendency worsens as we age, and it can become difficult to overcome within 4 to 6 weeks.

### Proximal Interphalangeal Joint

The proximal interphalangeal (PIP) joint is a single-axis hinge or ginglymus joint that allows for flexion and extension while resisting any motion in the coronal plane. Similar to the MCP joint, the PIP joint consists of the capsule, two proper collateral

**Figure 2**

Radial dissection of digit demonstrating collateral ligaments. PIP = proximal interphalangeal

ligaments, two accessory ligaments, and the volar plate.

The dorsal capsule of the PIP joint is connected to the central tendon, which also provides a dorsal stabilizing force. The collateral ligaments arise from a small recess in the head of the proximal phalanx and insert onto the volar aspect of middle phalanx and the volar plate. Unlike the MCP joint, no cam effect is present and the tension of the collateral ligaments is uniform throughout flexion and extension of the joint.

Also, unlike the MCP joint, the volar plate has two distinct regions: the fibrocartilaginous distal part is the articular component that is quadrangular in shape and a thin membranous proximal component. The lateral aspects of the distal volar plate anchor the collaterals to the middle phalanx. Also a proximal expansion exists on both sides of the volar plate margins which extend to the volar margins of the proximal phalanx, which are referred to as checkreins or check ligaments. They are unique to the PIP joint and limit hyperexten-

sion, compared with the MCP or distal interphalangeal (DIP) joints where they are not present.

Whereas the MCP joints tend to develop extension contractures, the PIP joints most commonly develop flexion contractures. This is a function of both overpull of more powerful flexor tendons and the flexed posture of the PIP joints. Over time, volar plate, collateral ligaments, and flexor sheath contractures can contribute to chronic PIP flexion contractures.

### Distal Interphalangeal Joint

The DIP joint is also a single axis hinge or ginglymus joint. The joint capsule is reinforced by the collateral ligaments that extend from the head of the middle phalanx to the sides of the volar plate, with the accessory ligaments lying more volar. The volar plate also serves as an accessory insertion for the flexor digitorum profundus tendon. Additionally, the terminal extensor mechanism attaches the dorsal edges of the collateral ligaments and provides dorsal support.

### Interosseous Muscles

Seven intrinsic interosseous muscles are present in the hand (four dorsal and three volar), and their tendons run dorsal to the deep transverse intermetacarpal ligaments. The dorsal interossei are abductors, lying on the radial aspect of the index and middle fingers and the ulnar aspect of the middle and ring fingers, with the abductor digiti quinti as the abductor to the small finger. Each dorsal interosseous, apart from the third, contains a superficial head arising from the metacarpals, inserts deeply by a medial tendon onto the base of the proximal phalanx and are deep to the sagittal band. This functions to abduct and weakly flex the proximal phalanx. The deep head becomes the lateral tendon, inserting into the transverse fibers and lateral band, which are superficial to the sagittal bands. This functions to flex and weakly abduct the proximal phalanx and extend the middle and distal phalanges. The transverse fibers from each lateral band arch dorsally and act to flex the proximal phalanx. More distally, the oblique fibers from the lateral bands overlie the distal third of the proximal phalanx to insert at the base of the middle phalanx and act to extend the middle phalanx. The lateral bands are then joined by the lateral slips of the extensor tendon and form the conjoined lateral bands, which unite at the distal third of the middle phalanx to form the terminal tendon, which inserts at the base of the distal phalanx to extend the DIP joint.

The three palmar interossei do not have separate muscle bellies and do not insert onto the proximal phalanx. Instead, they insert onto the ulnar lateral band of the index and radial lateral band of the ring and little fingers. They act to adduct the index, ring, and little fingers toward the middle finger; assist in flexion of the



proximal phalanx; and add to extension of the middle phalanx because of their insertion on the lateral bands.

## Lumbricals

The lumbrical muscles arise from the flexor digitorum profundus (FDP) tendons, course radially, pass volar to the deep transverse metacarpal ligaments, and join the radial lateral band at the proximal phalanx. The lumbricals contribute to the extension of the PIP and DIP joints and minimally to MCP joint flexion.

## Extrinsic Extensors

The only extensors of the proximal phalanges are the four extensor digitorum communis (EDC) tendons, the extensor indicis proprius, and the extensor digiti quinti. The sagittal bands arise from the extensor tendon at the MCP joint and attach volarly onto the moorings on the volar plate and base of the proximal phalanx. When the EDC muscle contracts, the proximal phalanx is extended via torque and extension moment arm generated by the extensor tendon continuation to the extensor hood and the middle phalanx.<sup>2</sup> Distal to the MCP joint, the extensor tendon divides into two lateral slips and one central slip. The central slip inserts into the central tubercle of the dorsal base of the middle phalanx, extending the PIP joint, whereas the lateral slips combine with the lateral bands at the distal proximal phalanx to form the conjoined lateral band. The conjoined lateral bands join at the distal middle phalanx to form the terminal tendon, which inserts into the base of the distal phalanx, extending the DIP joint.

## Clinical Evaluation and Assessment

The evaluation and management of joint stiffness must include an under-

standing of the anatomical components and the mechanism of injury to allow anticipation of what structures might need to be addressed in therapy, splinting, and surgery. The clinical examination should begin with a visual inspection of possible barriers to motion, including skin contractures, previous scars, and edema. Additionally, Complex Regional Pain Syndrome should be suspected in patients with unexpectedly intense pain with minimal relief from analgesics, allodynia, hyperalgesia, trophic changes, and/or difficulty sleeping. The intense pain and edema can result in permanent stiffness and functional deficits.<sup>3</sup>

Next, motion of each joint can be evaluated. Soft-tissue barriers to flexion include contracture of the dorsal capsule and/or the collateral ligaments, intrinsic tightness, and adherent extensor tendons. Soft-tissue blocks to extension include checkrein or volar plate contractures and adherent flexor tendons. If active and passive motion is equally limited, tendon adhesions cannot be fully evaluated until the joint is completely mobilized. If passive extension exceeds active extension, then insufficiency or scarring of extrinsic extensor tendons should be suspected. Similarly, if passive flexion exceeds active flexion, flexor tendon incompetence or adhesions should be suspected.

After evaluation of ROM, the extrinsics and intrinsics should be tested. Extrinsic extensor tendon tightness results in diminished excursion of the EDC, extensor indicis proprius, and/or extensor digiti quinti, and hence limits the simultaneous flexion of the MCP and PIP joints. When the wrist and MCP joints are flexed, passive flexion of the interphalangeal (IP) joints is difficult, but this same joint flexion will usually be improved when the wrist is extended. If this is not seen, then intrinsic MCP and/or PIP joint contractures should be suspected. Similarly, extrinsic flexor tendon tightness may be present if IP joint

extension is difficult with wrist and MCP joint extension. Intrinsic tightness is tested with the Bunnell intrinsic tightness test. This is considered positive when PIP joint flexion is diminished with the MCP joint held in extension compared with when the MCP joint is held in flexion. Additionally, tightness of PIP joint flexion with MCP joint ulnar deviation compared with radial deviation signifies a more notable contribution of lumbrical tightness rather than the interossei, because the lumbricals lie radially and are therefore under more tension with ulnar deviation.

Imaging with standard finger radiographs is imperative to assess for bony block to motion, joint incongruity, or presence of arthritis contributing to stiffness. Advanced imaging is usually unnecessary unless evaluating for joint incongruity (CT) or tendon rupture (MRI).

## Nonsurgical Treatment

Nonsurgical treatments can obviate the need for surgery. Treatment goals should be individualized for each patient and digit, because some patients may be able to function well without full flexion and extension. Ulnar-sided digits typically require a greater ROM than radial-sided digits because of their contribution to grasp and grip. Additionally, the proximity of the thumb can assist with pinching and grasping despite some stiffness in the radial digits. Nonsurgical treatment includes active-assist and passive ROM exercises, buddy taping, splinting, and serial casting.<sup>4</sup>

Splints are classified into static, serial static, static progressive, or dynamic splints. Static splints maintain the hand and digits in one position and can be worn continuously or removed when doing exercises. Extension splints for flexion contractures are especially useful at night when fingers assume a flexed posture

during sleep. Splints may also act as blocking splints, which try to improve ROM by isolating a specific joint or joints. Serial static splints apply a force to the stiff joint at a position of maximal stretch and require adjustments and remolding after the tissues have accommodated and require additional stretching force. Static progressive splints are similar but use the principle of three-point application of force and can allow for change in splint positioning through a gear or ratchet without custom molding. To optimize ROM, adjustments in the splints typically are made weekly by occupational therapists. Dynamic splints apply elastic traction, typically using rubber bands or springs, to create a stretching force while permitting motion. They are effective but can be painful and often tolerated for only a short duration of time (eg, 10 to 15 min per hour). These also offer the ease of removal for hygiene purposes and less frequent therapy sessions compared with serial casting.

The MCP joints should be immobilized in flexion to maintain the length of the collateral ligaments. In the rarer cases of flexion contracture of the MCP joint, dynamic and static extension progressive splinting with hand therapy is often clinically effective.

Nonsurgical management of PIP joint contractures is the first line of management for contractures of less than 45°, because contractures greater than this may not tolerate extension splints owing to risk of skin breakdown.<sup>5,6</sup> Furthermore, chronic fixed contractures are unlikely to respond to any nonsurgical treatment. Management modalities for PIP joint contractures include serial digital cylinder casts or custom splints, both static and dynamic.<sup>7</sup> Glasgow et al<sup>8</sup> examined the duration of splinting for PIP contractures, noting that no notable difference exists in ROM between splint time of

6 to 12 hours and that of 12 to 16 hours. Also, they found that patients had difficulty wearing splints for longer than 12 hours per day. In addition, Glasgow et al<sup>9</sup> demonstrated that orthotic treatment for an average of 12 weeks maximized the extent of contracture resolution for flexion contractures, although extension deficits continued to demonstrate slow and progressive improvement beyond 17 weeks.

Most finger contractures show measurable progress within 1 month of extensive therapy. Although splinting and casting may be continued for 5 to 6 months, if no notable progress has been made after 3 months, conservative treatment is unlikely to be effective and surgery will be required.<sup>6,7</sup> In addition, a rigid bony block to passive ROM will require surgery if correction is desired by the patient.

## Surgical Treatment

Surgical management of the stiff digit should be considered when nonsurgical treatment has plateaued or failed. Additionally, soft-tissue swelling and inflammation should be diminished as much as possible and articular surfaces should be as congruent as possible before surgery. The surgeon must have a thorough discussion with the patient beforehand regarding expectations and the importance of compliance with postoperative therapy. It is imperative for the patient to be committed to their postoperative rehab to improve outcomes, and the patient's diligence with previous nonsurgical therapy may be a surrogate indicator for their postoperative compliance.

Whenever possible, wide awake local anesthesia no tourniquet technique with lidocaine or bupivacaine should be used to assess active ROM intraoperatively.<sup>10</sup> If sedation is used, the timing and degree of sedation can

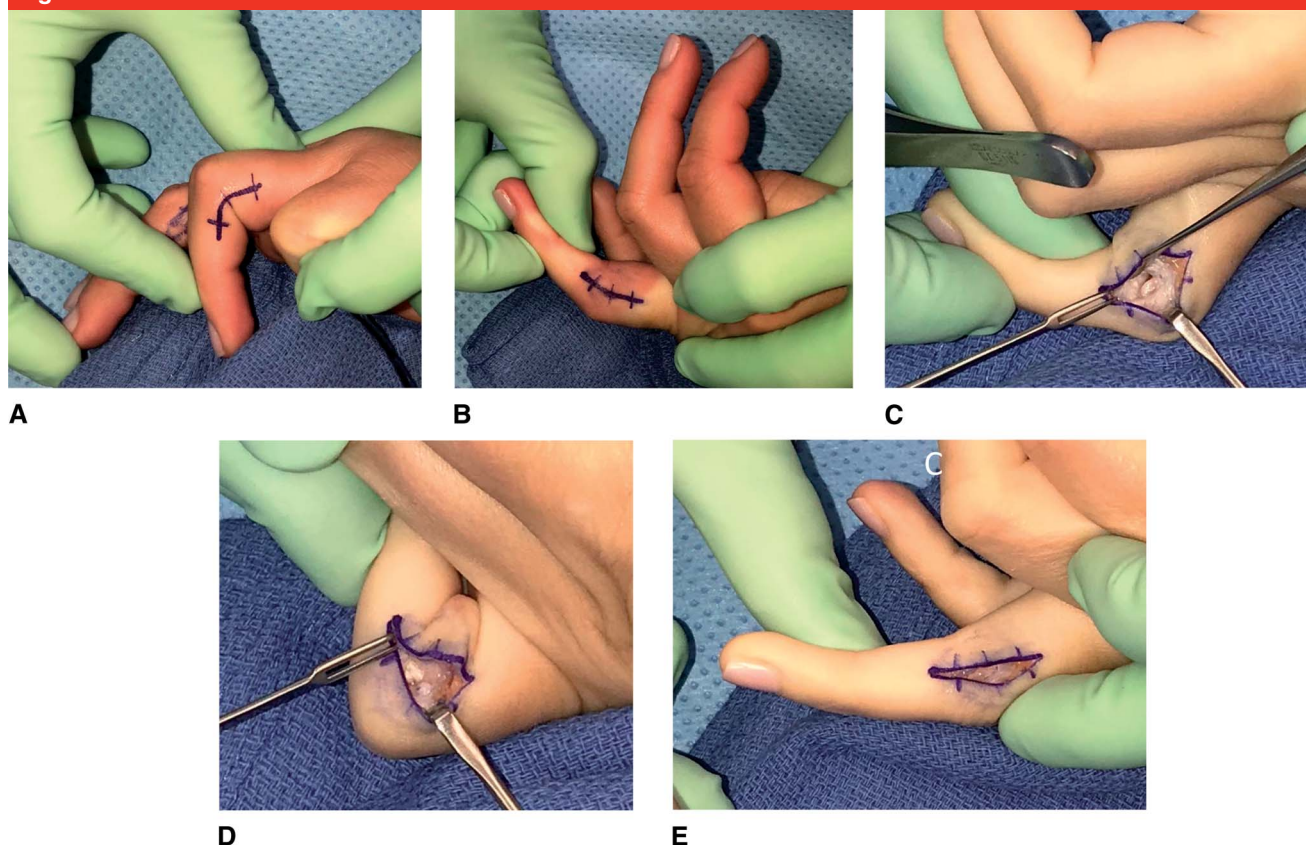
often be titrated so that the patient is initially more sedated and later can range the digit when asked. If regional anesthesia is used, a proximal incision may be made to allow for traction of the flexor tendons.

For MCP joint extension contractures, Buch<sup>11</sup> and Shin and Amadio<sup>1</sup> have published procedures using a dorsal approach. This consists of dividing the sagittal bands and retracting the extensor tendon to expose the joint. A dorsal capsulotomy is then performed with possible release of the dorsal part of the collateral ligaments as needed. The sagittal bands are subsequently repaired during closure. Alternatively, a dorsal capsulotomy may be performed proximal to the sagittal bands, obviating the need for later repair.

MCP joint flexion contractures secondary to intrinsic contracture are infrequent but may require a proximal intrinsic release. In the latter, a dorsal incision is made over the MCP joint and the transverse and oblique fibers of the intrinsic mechanism are released proximal to the joint while preserving the extrinsics and sagittal hood.<sup>12</sup>

Boyer and colleagues have previously outlined a systematic surgical approach for stiffness based on passive and active PIP joint ROM, assuming no bony block to motion:<sup>13</sup>

- (1) Limited passive flexion and extension: This suggests both dorsal (limiting joint flexion) and volar (limiting joint extension) pathology. The authors most often use a midaxial approach ulnarly and radially to address both. However, if notable flexor tendon adhesions are suspected, then a volar approach is used to gain broader access. With the midaxial approach, 2 cm incisions are centered over the PIP joint. The lateral bands are identified and carefully feathered off of the underlying capsular and periosteal tissue. Once mobilized,

**Figure 3**

**A and B**, Preoperative passive range of motion of 35° to 90°, with both midaxial incisions marked. **C**, After excision of the radial collateral ligament en bloc, the radial condyle of the proximal phalanx becomes visible as does the thickened volar plate. **D**, Passive flexion has improved to 110° after excision of the radial collateral ligament. **E**, Passive extension has minimally improved because of the intact volar plate.

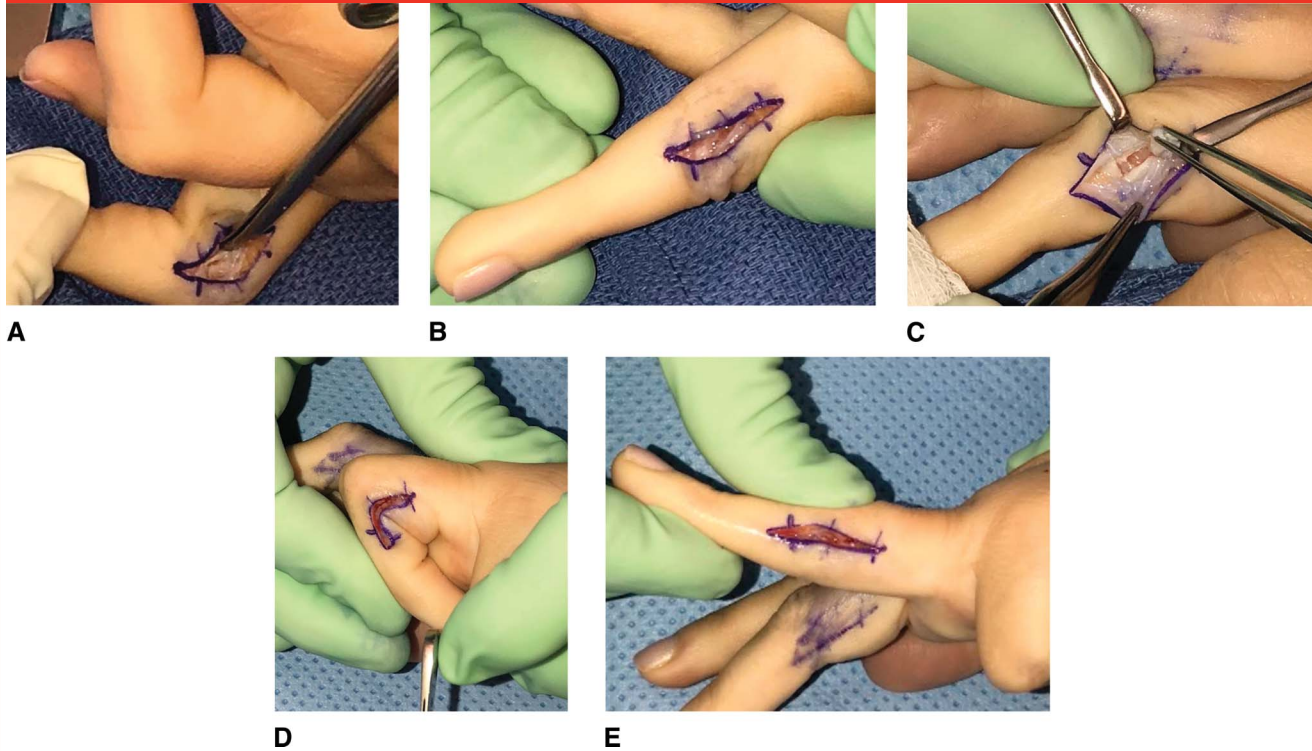
the lateral bands are retracted dorsally and the abnormally thickened collateral ligaments are completely excised.<sup>14</sup> Then, the thickened volar plate can be addressed. The flexor tendons are often adherent and immediately adjacent to the volar plate, so dissecting scissors are used to identify and separate the tendons from the volar plate. The volar plate is then completely divided at the mid to distal level. This maneuver will automatically release the accessory collateral ligament. Additionally, the volar aspect of the flexor sheath at the level of the PIP joint may be contracted and may need to be released, although

this flimsier tissue will often tear with joint manipulation (Figures 3 and 4). To address isolated dorsal pathology (capsular contracture and extensor tendon adhesions), a dorsal or dorso-lateral approach may be used instead of the midaxial incisions, although these are far less common. If intrinsic tightness is present causing a PIP extension contracture, a distal intrinsic release will be required.<sup>12,15</sup> This can be accomplished with midaxial incisions along the radial and/or ulnar aspects of the digit (depending on which intrinsic is tighter) or a single dorsal incision of the proximal phalanx. The oblique fibers and lateral bands

are identified and excised, and the release begins distally and progresses proximally along the distal third of the proximal phalanx, taking care to retain the intrinsic mechanism responsible for MCP flexion (transverse fibers) and the central slip. Extrinsic tightness or dorsal joint contracture will necessitate dorsal capsulotomy, release of the dorsal portion of the collateral ligaments,<sup>11</sup> and release of the extensor tendon from the periosteal adhesions—as is common with phalangeal fractures—taking care to preserve the central slip which may be damaged with these maneuvers. After restoration of passive motion, the amount of active flexion and



Figure 4



**A,** Separation of the flexor tendons (protected by scissor tips) from the thickened volar plate. **B,** Near full passive extension achieved after division of the volar plate. **C,** Attention now turned to the excision of the ulnar collateral ligament. The ligament has been detached distally and remains intact at its origin, soon to be detached as well. **D and E,** Full passive range of motion has been achieved.

extension must be determined if possible. If full finger flexion is lacking, a flexor tenolysis may need to be performed.

- (2) Limited active flexion and extension; full passive ROM: This suggests pathology of the flexor and extensor tendon mechanisms, which may be secondary to tendon adhesions or rupture. Adhesions are addressed with tenolysis, and tendon rupture is managed with repair or staged reconstruction.
- (3) Limited passive extension; full active and passive flexion: This is approached in a similar manner as in (1) by releasing the contracted volar tissues sequentially as necessary.
- (4) Limited passive flexion and active extension; full passive extension: This is secondary to

dorsal pathology, likely because of extensor tendon adhesions with or without a contracted dorsal joint capsule. A dorsal approach with dorsal capsulotomy and lysis of the extensor tendon adhesions should restore full extension.

- (5) Limited passive extension and active flexion; full passive flexion: This is secondary to palmar pathology, potentially secondary to flexor tendon adhesions, skin contracture, tight collateral ligaments, or a contracted volar plate. In this case, a volar approach is used with releases in a similar manner as described in (1).
- (6) Limited active flexion with full active extension and passive flexion: This is likely secondary to flexor tendon adhesions or possibly tendon disruption. The

flexor tendons should be explored for tenolysis, primary repair, or reconstruction.

Release of severe PIP and MCP flexion contractures may leave a palmar open defect once the finger is fully extended, necessitating skin grafting or advancement flaps.<sup>16</sup> Additionally, some patients with contracted scars may require a Z-plasty for lengthening.<sup>17</sup>

External fixators have also been used to correct PIP joint flexion contractures.<sup>18,19</sup> These are placed in the proximal and middle phalanges and provide a constant joint distraction force transmitted through bone without skin compromise. White et al<sup>20</sup> described a method using two mini-external fixators applied under fluoroscopic guidance to the dorsum of the middle and proximal phalanges, with elastic bands passed

between these two constructs, generating a traction extension force across the joint. Craft et al<sup>21</sup> described using the “Digit Widget” (Hand Biomechanics Laboratory), a dynamic extension device applied using fluoroscopic guidance, which similarly provides a gradual extension force for PIP flexion contractures. Disadvantages of these external devices is the risk of postoperative pin site infection and need for strict patient compliance.

DIP joint contractures have less effect on composite digital ROM and rarely require management, unless associated with swan neck, boutonniere, or chronic mallet deformities.<sup>1</sup> If DIP release is indicated, the culprit is usually a contracted volar plate and adherent flexor tendon. A simple lateral approach to the DIP joint with volar plate release and tenolysis of the flexor tendon at that level is usually effective.

Within a few days after surgery, patients should start a therapy program to maintain the intraoperative ROM. Use of dynamic and static splints and compression digit sleeves are preferred by the authors. Despite no clear clinical evidence in the literature, consideration may be given to using NSAIDs or a short prednisone taper to help minimize edema and pain, with hopes to improve final ROM.

## Outcomes

The goal of the management of the stiff finger is restoring a stable, mobile, and pain-free joint. Nonsurgical treatment is effective in most patients, with Weeks et al<sup>22</sup> reporting that up to 87% of PIP and MCP joint contractures were managed successfully with hand therapy exercises and dynamic splinting. In this series, 82% of patients with MCP joint contractures responded favorably within 2 weeks of starting therapy, with an average increase in ROM ranging from 11° to 42° depending

on the digit. For PIP flexion contractures less than 45°, an improvement of 16° and 18° after 10 weeks and up to 4 months of splinting, respectively, can be achieved.<sup>23,24</sup> However, stiffer joints and long-standing chronic contractures had poorer results.<sup>24</sup>

For MCP joint extension contractures, Gould and Nicholson<sup>25</sup> reported a mean gain of 21° and 29° of active and passive motion, respectively, after MCP joint capsulotomies. In addition, Buch<sup>11</sup> noted that all patients in their series gained at least 30° of flexion at follow-up.

PIP joint contractures managed with open release have shown mixed results. Poorer outcomes are associated with older age, higher number of procedures, and notable joint deformity.<sup>7</sup> Ghidella et al<sup>26</sup> demonstrated an average improvement of only 5.8° after PIP contracture release, with 31% of patients requiring revision surgery because of loss of motion. Abbiati et al,<sup>27</sup> however, noted that 50% of patients in their series achieved complete extension. Similar results were shown by Diao and Eaton<sup>14</sup> after complete collateral ligament excision for PIP contractures in 16 patients, in which improvement from 38° of joint ROM to 78° was seen.

External fixators have shown promising results in the management of PIP contractures. Houshian et al<sup>19</sup> reported a mean gain in active ROM of 67° (40° improvement in joint extension and 25° in joint flexion) at a mean of 54-month follow-up in patients with chronic PIP flexion contractures. One explanation for these improved outcomes is that postoperative adhesions and scar tissue may form after an open approach which is not the case with an external fixator.

## Summary

A comprehensive understanding of the anatomy and examination is

essential when evaluating the stiff finger. Initial nonsurgical treatment is warranted but may have poorer results in patients with more severe or chronic contractures. Nonsurgical management does not have a defined end point, but surgery should be considered for limited improvement after 3 to 6 months of conservative management. Surgical options include soft-tissue releases depending on the specific pathology, whereas PIP flexion contractures may also be managed using external fixators. Regardless of the treatment, to achieve optimal patient satisfaction, expectations and adherence to therapy protocols should be thoroughly discussed with each patient.

## References

References printed in **bold type** are those published within the past 5 years.

1. Shin AY, Amadio PC: The stiff finger. In: Wolfe SW, Hotchkiss RN, Pederson WC, Kozin SH, Cohen MS: *Green's Operative Hand Surgery*. Philadelphia, PA, Elsevier/Churchill Livingstone, 2017.
2. Marshall TG, Sivakumar B, Smith BJ, Hile MS: Mechanics of metacarpophalangeal joint extension. *J Hand Surg Am* 2018;43:681.e1-681.e5.
3. Patterson RW, Li Z, Smith BP, Smith TL, Koman LA: Complex regional pain syndrome of the upper extremity. *J Hand Surg Am* 2011;36:1553-1562.
4. Yang G, McGlinn EP, Chung KC: Management of the stiff finger: Evidence and outcomes. *Clin Plast Surg* 2014;41:501-512.
5. Callahan AD, McEntee P: Splinting proximal interphalangeal joint flexion contractures: A new design. *Am J Occup Ther* 1986;40:408-413.
6. Hogan CJ, Nunley JA: Posttraumatic proximal interphalangeal joint flexion contractures. *J Am Acad Orthop Surg* 2006;14:524-533.
7. Houshian S, Jing SS, Chikkamuniyappa C, Kazemian GH, Emami-Moghaddam-Tehrani M: Management of posttraumatic proximal interphalangeal joint contracture. *J Hand Surg Am* 2013;38:1651-1658.



8. Glasgow C, Fleming J, Tooth LR, Peters S: Randomized controlled trial of daily total end range time (TERT) for Capener splinting of the stiff proximal interphalangeal joint. *Am J Occup Ther* 2012;66:243-248.
9. Glasgow C, Fleming J, Tooth LR, Hockey RL: The long-term relationship between duration of treatment and contracture resolution using dynamic orthotic devices for the stiff proximal interphalangeal joint: A prospective cohort study. *J Hand Ther* 2012;25:38-46.
10. Lalonde D: Minimally invasive anesthesia in wide awake hand surgery. *Hand Clin* 2014;30:1-6.
11. Buch VI: Clinical and functional assessment of the hand after metacarpophalangeal capsulotomy. *Plast Reconstr Surg* 1974;53:452-457.
12. Paksima N, Besh BR: Intrinsic contractures of the hand. *Hand Clin* 2012;28:81-86.
13. Hammert WC: *American Society for Surgery of the H. ASSH Manual of Hand Surgery*. Philadelphia, PA, Lippincott Williams & Wilkins, 2012.
14. Diao E, Eaton RG: Total collateral ligament excision for contractures of the proximal interphalangeal joint. *J Hand Surg Am* 1993;18:395-402.
15. Harris C Jr, Riordan DC: Intrinsic contracture in the hand and its surgical treatment. *J Bone Joint Surg Am* 1954;36-A:10-20.
16. Tseng J, Lin YT: Neurovascular advancement flap to release flexion contracture of the proximal interphalangeal joint. *J Hand Surg Am* 2017;42:300.e1-300.e5.
17. Hundeshagen G, Zapata-Sirvent R, Goverman J, Branski LK: Tissue rearrangements: The power of the Z-plasty. *Clin Plast Surg* 2017;44:805-812.
18. Houshian S, Chikkamuniyappa C, Schroeder H: Gradual joint distraction of post-traumatic flexion contracture of the proximal interphalangeal joint by a mini-external fixator. *J Bone Joint Surg Br* 2007;89:206-209.
19. Houshian S, Jing SS, Kazemian GH, Emami-Moghaddam-Tehrani M: Distraction for proximal interphalangeal joint contractures: Long-term results. *J Hand Surg Am* 2013;38:1951-1956.
20. White JW, Kang SN, Nancoo T, Floyd D, Kambhampati SB, McGrouther DA: Management of severe Dupuytren's contracture of the proximal interphalangeal joint with use of a central slip facilitation device. *J Hand Surg Eur Vol* 2012;37:728-732.
21. Craft RO, Smith AA, Coakley B, Casey WJ III, Rebecca AM, Duncan SF: Preliminary soft-tissue distraction versus checkrein ligament release after fasciectomy in the treatment of dupuytren proximal interphalangeal joint contractures. *Plast Reconstr Surg* 2011;128:1107-1113.
22. Weeks PM, Wray RC Jr, Kuxhaus M: The results of non-operative management of stiff joints in the hand. *Plast Reconstr Surg* 1978;61:58-63.
23. Hunter E, Lavery J, Pollock R, Birch R: Nonoperative treatment of fixed flexion deformity of the proximal interphalangeal joint. *J Hand Surg Br* 1999;24:281-283.
24. Prosser R: Splinting in the management of proximal interphalangeal joint flexion contracture. *J Hand Ther* 1996;9:378-386.
25. Gould JS, Nicholson BG: Capsulectomy of the metacarpophalangeal and proximal interphalangeal joints. *J Hand Surg Am* 1979;4:482-486.
26. Ghidella SD, Segalman KA, Murphey MS: Long-term results of surgical management of proximal interphalangeal joint contracture. *J Hand Surg Am* 2002;27:799-805.
27. Abbiati G, Delaria G, Saporiti E, Petrolati M, Tremolada C: The treatment of chronic flexion contractures of the proximal interphalangeal joint. *J Hand Surg Br* 1995;20:385-389.