

# Surgical Management of Neuromas of the Hand and Wrist

Steven Regal, MD

Peter Tang, MD, MPH

## Abstract

Neuromas of the hand and wrist are common causes of peripheral nerve pain. Neuromas are formed after the nerve sustains an injury, and they can be debilitating and painful. The diagnosis is made by a thorough history and physical examination. The treatment options are quite varied, but conservative measures tailored to the patient should be initiated first. No surgical treatment has been proven superior to others or to nonsurgical treatment.

Neuromas of the hand and wrist can be a mentally and physically disabling condition for patients. A neuroma is the abnormal growth of nerve tissue that consists of a disorganized architecture of axons, Schwann cells, macrophages, and fibroblasts as a result of the biologic response to nerve trauma or an unsuccessful nerve repair (Figure 1). Neuroma formation may result secondary to a peripheral nerve injury, such as a laceration, crush injury, chronic irritation or stretch, or the result of a nerve repair. Patients who experience a digit amputation have a reported 2.7% to 30% incidence of developing a symptomatic neuroma.<sup>1,2</sup> In a nerve injury where the axon is disrupted, the distal portion of the axon will undergo Wallerian degeneration. The proximal portion of the neuron sprouts toward the empty neural tube and will grow 1 to 2 mm per day to restore the nerve's function. A neuroma will form if the proximal neuron fails to effectively reach the distal nerve end.<sup>3,4</sup> With more than 150 different treatment options for symptomatic neuromas, the optimal management remains unknown and hence, the challenge. This article reviews the nonsurgical and surgical management of symptomatic neuromas of the hand and wrist.

## Etiology

Sunderland classified nerve injuries based on the histologic structure of nerves and expanded Seddon's neurotmesis category with two additional degrees of injury. In Sunderland's<sup>5</sup> third- and fourth-degree injuries, the endoneurium is disrupted and the epineurium remains intact, leading to disorganized axon growth and fusiform swelling at this site (Figure 2). Yuksel et al<sup>6</sup> hypothesized that the perineurium is a barrier to regenerating axon so when the perineurium is damaged, fascicular escape can occur. With escape, the regenerating axons grow into the epineural tissue in a disorganized fashion along with Schwann cells, fibroblasts, and blood vessels. The regenerating axons form the patterns of whorls, spirals, and convolutions, which are characteristics of neuroma histology.

## Clinical Evaluation (Diagnosis)

### History and Physical Examination

A thorough history and physical examination is critical in establishing the correct diagnosis. Often, a surgical

From the Division of Hand, Upper Extremity, and Microvascular Surgery, Department of Orthopaedic Surgery, Allegheny General Hospital, Pittsburgh, PA.

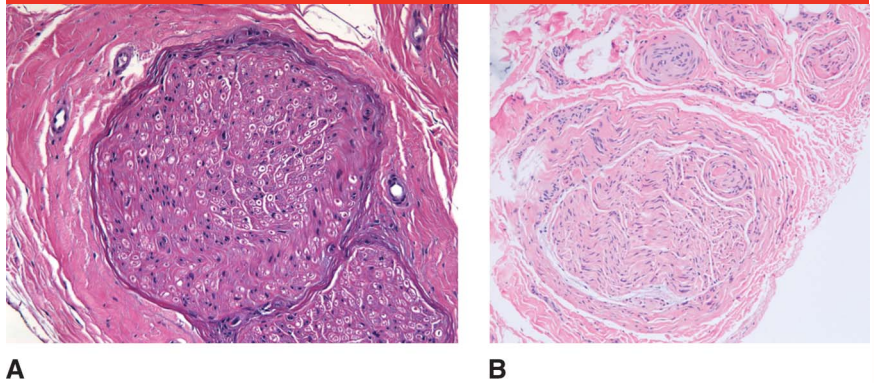
Dr. Tang or any immediate family member is a member of a speakers' bureau or has made paid presentations on behalf of AxoGen and Synthes; serves as a paid consultant to Globus Medical; and has received research or institutional support from AxoGen. Neither Dr. Regal nor any immediate family member has received anything of value from or has stock or stock options held in a commercial company or institution related directly or indirectly to the subject of this article.

*J Am Acad Orthop Surg* 2019;27: 356-363

DOI: 10.5435/JAAOS-D-17-00398

Copyright 2018 by the American Academy of Orthopaedic Surgeons.

or traumatic scar can localize the clinician's examination to the site of the neuroma. Hallmark features of neuroma pain include spontaneous pain; hyperalgesia or allodynia to touch, pressure, or movement; and the sensation of a burning or electrical pain.<sup>4,7</sup> A positive Tinel sign is often found at the site of the neuroma, and the area distal to this will have altered sensation (hypoesthesia, hyperalgesia, or anesthesia).<sup>4,8,9</sup> A modified Hendler back pain rating scale is a useful tool to evaluate neuroma pain with prognostic implications. The test is composed of three components: a body diagram pain drawing, a numerical scale quantifying pain, and a list of pain descriptors (Figure 3). Patients who have significant hand dysfunction that negatively impacts their daily lives will have a pain drawing on the body diagram that does not correspond to the anatomic course of a peripheral nerve, have a score of 20 or more points on the numerical scale, and use three or more adjectives to describe the pain. Patients

**Figure 1**

Electron microscopic image of peripheral nerve (A). Electron microscopic image of neuroma showing hypertrophic nerves with perineural fibrosis (B).

who have all three of the components experience an exaggerated response to pain and are not surgical candidates. Patients who only have one of the above components will likely have a good outcome, whereas those who have two of the three are likely to have suboptimal results. The modified Hendler back pain rating scale helps the practitioner differentiate organic from functional pain, although no studies examining

the surgical versus nonsurgical success rates exist.<sup>9-11</sup>

## Management

### Nonsurgical Management

It is important for the surgeon to have knowledge of nonsurgical management of neuromas of the hand and wrist. Conservative options should be exhausted before any surgical intervention, and it may be the treatment of

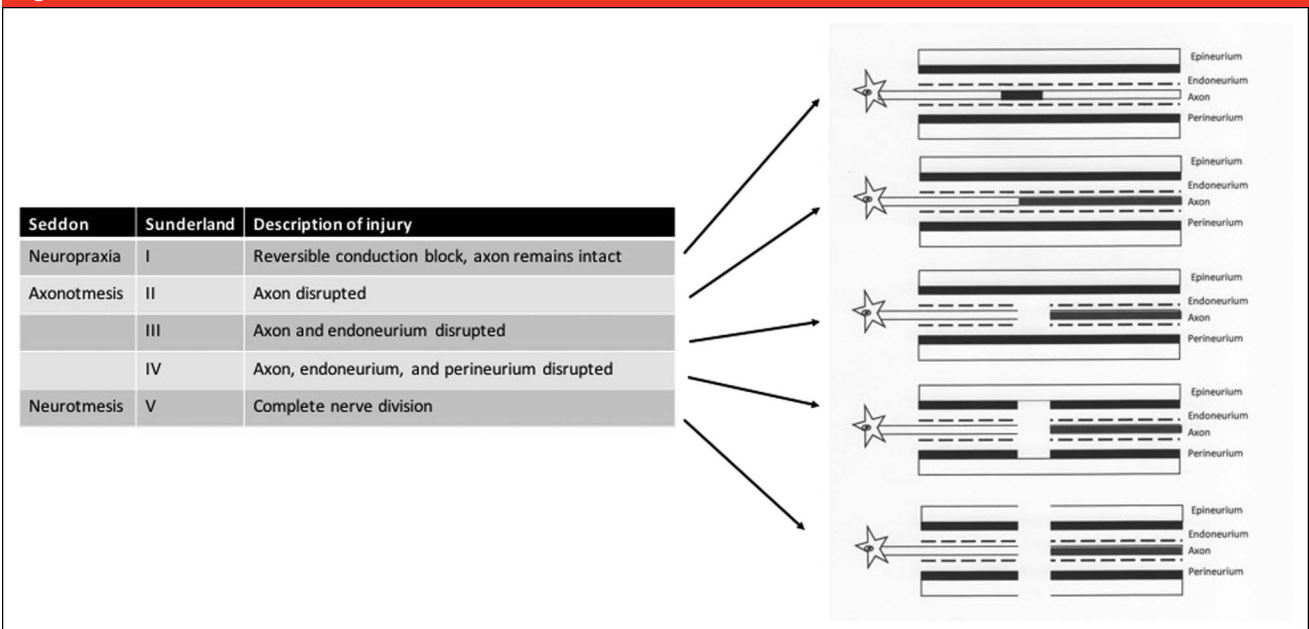
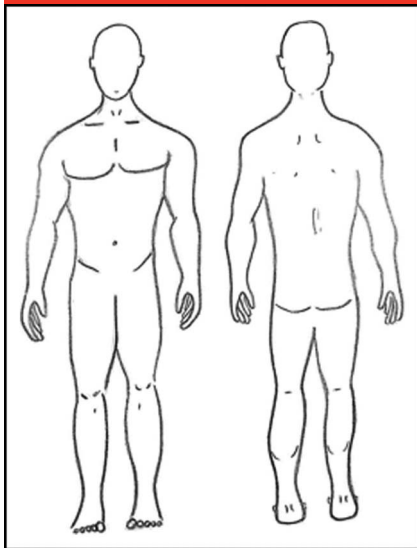
**Figure 2**

Diagram representing Seddon and Sunderland degrees of nerve injury.

**Figure 3**

Body diagram to be used by patients to draw location and direction of pain.

choice for those who cannot tolerate a surgery or choose not to have surgery. Physical therapy modalities, such as percussion, massage, and ultrasonography, have been reported to decrease neuroma pain either through desensitization or reducing inflammation and local scarring around the nerve.<sup>12-14</sup> Desensitization protocols often progress from soft, nonirritating materials, such as paraffin wax, to more noxious stimuli like constant touch or pressure that assists in the physiologic and psychologic return to normalcy over time. The use of vibration can stimulate A- $\beta$  fibers and “block out” painful C fiber activity.<sup>11,15</sup> Analgesic and neuropathic agents are alternative nonsurgical options that can be prescribed early following any traumatic nerve injury to optimize prognosis and reduce chronic pain in the upper limb.<sup>16</sup>

Steroid injections have been used to treat neuromas with varying degrees of success, but most studies are focused on the lower extremity. A 2014 study found that 7 of 14 patients with lower extremity amputation neuroma pain had >50% reduction in pain after an ultrasonography-

guided steroid injection.<sup>17</sup> Rasmussen et al<sup>18</sup> reported on 51 interdigital neuromas of the foot treated with a single steroid injection with 4-year follow-up; 80% had pain relief within the first 3 months. However, only 11% had lasting improvement in pain at 4 years, and 47% eventually underwent surgical excision. Although the injection of local anesthetic and/or corticosteroid may not provide a definite treatment, it may be useful for diagnostic purposes.

Pharmacologic management of neuropathic pain consists of numerous classes of medications, each with their own advantages, disadvantages, adverse effects, and different efficacy rates among patients. The first medications that proved efficacious for neuropathic pain in placebo-controlled trials were the tricyclic antidepressants. A recent Cochrane review of 61 randomized controlled trials examining the analgesic effect of antidepressants on neuropathic pain concluded that tricyclic antidepressants are effective in treating neuropathic pain; one out of every three patients treated will get at least moderate pain relief.<sup>19</sup> Other classes of medications include selective norepinephrine and serotonin reuptake inhibitors (venlafaxine, duloxetine), gabapentinoids (gabapentin, pregabalin), opioids (oxycodone, tramadol), antiepileptics (carbamazepine), and topical agents, such as lidocaine and capsaicin. These medications have been used to effectively treat and alleviate neuropathic pain. These medications should be started at low doses and gradually increased to avoid unwanted adverse effects.<sup>16,20</sup> An in-depth review of the pharmacologic treatment of neuropathic pain is beyond the scope of this article.

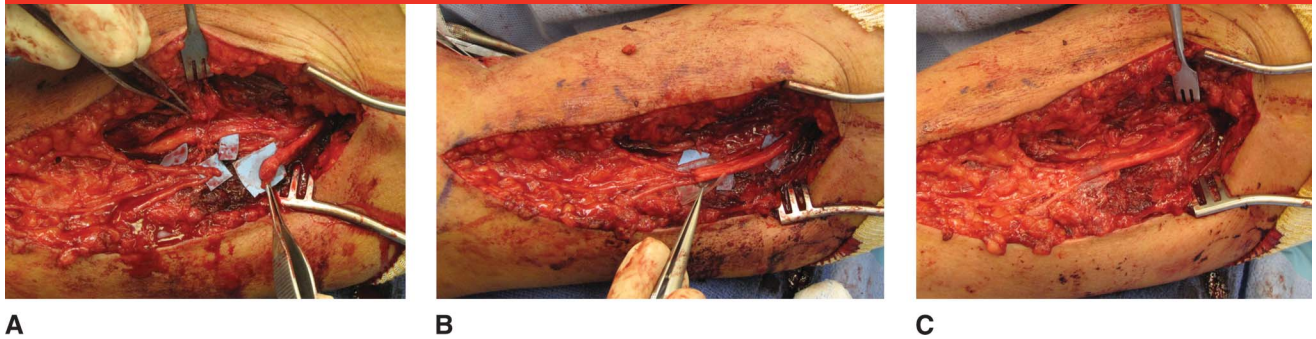### Surgical Management

Surgical management is best used in patients who have failed at least 6 months of conservative measures.<sup>8,9</sup> The existence of a large variety of

surgical techniques available to treat neuromas suggests that there is not a benchmark procedure to effectively treat all neuromas. The surgical management of painful neuromas should follow three basic principles that have been previously described by Nath and Mackinnon: (1) If there are appropriate distal nerve and sensory receptors available, a nerve graft can be used to guide the regenerating nerve stump distally into the native nerve and distal targets; (2) if a distal nerve or sensory receptors are not available and restoration of function is critical, innervated free tissue can be transferred to accept the regenerating nerve fibers from the injured nerve; and (3) if function of the injured nerve is not critical, the local tissue is not amenable for a nerve graft, or if the patient has had numerous previous unsuccessful surgical procedures for pain control, the neuroma can be resected and the proximal stump can be implanted into muscle, bone, or vein.<sup>9,11</sup> Historically, management of neuromas has focused on transposition of the resected neuroma into nonneural tissue. The availability of decellular nerve allograft makes reconstruction a more viable treatment as long as distal nerve ends are present (Figure 4).

### Neuroma Resection

Excision of a neuroma is one of the oldest described surgical techniques. Tupper and Booth<sup>21</sup> found that of 232 neuromas, 68% had excellent or satisfactory results from neurectomy alone. However, Guse and Moran<sup>22</sup> retrospectively reviewed 56 patients with a peripheral neuroma distal to the elbow and compared outcomes of neuromas that underwent nerve transposition into bone or muscle, simple excision, or nerve repair. The revision surgery rates and mean Disabilities of the Arm, Shoulder, and Hand (DASH) score were

**Figure 4**

Intraoperative photograph demonstrating an end-neuroma of the posterior cutaneous nerve of the arm caused iatrogenically during a posterior plating of a humeral shaft fracture performed 9 months ago (A) managed by neuroma resection and reconstruction with decellular nerve allograft (B) with placement of nerve wraps at the coaptation sites (C).

recorded. Transposition into bone or muscle had a revision surgery rate of 36%, whereas the DASH score was 22.4. Simple excision had a 47% revision surgery rate and a DASH score of 31.9, whereas nerve repair had an 11% revision surgery rate and a DASH score of 11.4. As a result of the high revision surgery rates and poor DASH scores, the authors' recommended against simple excision as a treatment option. As an alternative to resection alone, Tay et al<sup>23</sup> reported decreased neuroma formation in a rat model when the transected nerve was treated with short (4 seconds) or long (10 seconds) mono- or bipolar diathermy versus no treatment. The control groups had an 83% to 100% incidence of neuroma formation while both the short and long monopolar diathermy groups had a significant reduction in neuroma formation (30%). Only the long-duration bipolar diathermy had a significant reduction in neuroma formation (25%). No other published articles in the English language exist regarding the prevention/treatment of neuromas with diathermy.

### Neuroma Resection With Nerve Repair

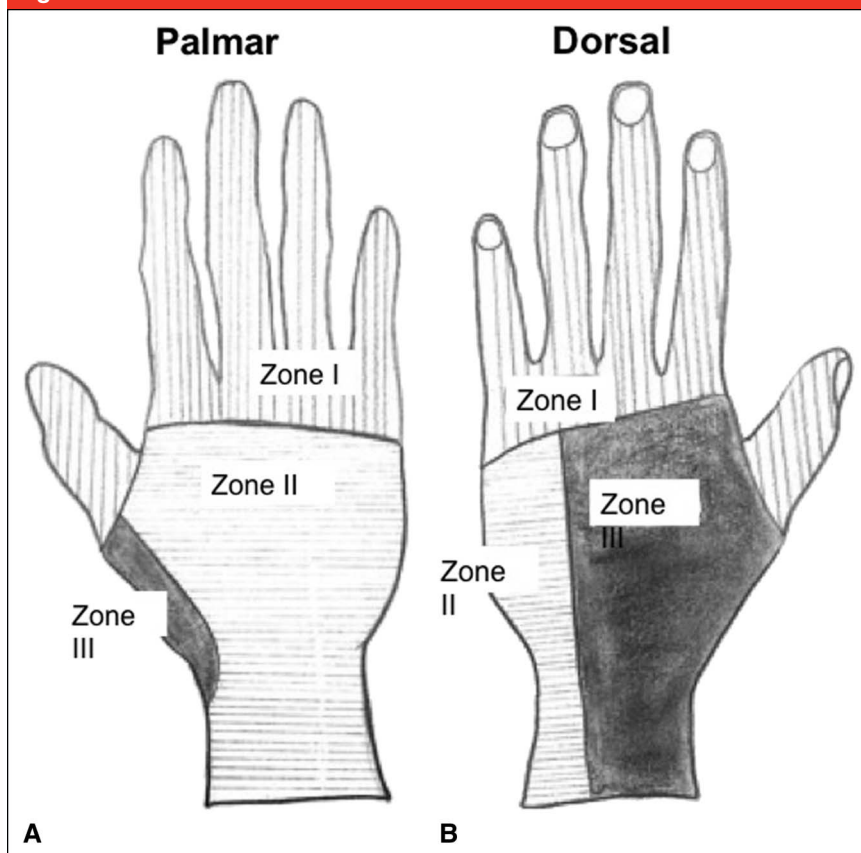
After resection of a neuroma, a tension-free primary suture repair is often not

possible. An end to side repair was described by Al-Qattan<sup>24</sup> to be used for neuroma prevention and treatment. Eight patients were treated with this technique (three had painful neuromas of the superficial radial nerve [SRN]) and were pain free with more than 16 months of follow-up. Thomsen et al<sup>25</sup> retrospectively reviewed 10 digital nerve neuromas treated with resection and bridging collagen conduits. The average quick-DASH score was 19.3; 50% had static 2-point discrimination less than 10 mm, and none had recurrence of Tinel sign at the final follow-up. A randomized, prospective study of 136 digital nerve transections treated with end-to-end repair with or without nerve autograft versus polyglycolic acid conduit showed no significant differences between the groups with greater than 70% excellent or good outcomes; a subanalysis of nerve gaps greater than 8 mm showed that the conduit group had significantly improved sensory recovery and moving two-point discrimination compared with the repairs done with sural nerve autograft, which left all those patient's with a persistent numbness on the lateral foot.<sup>26</sup> A recent randomized trial of 32 distal median and/or ulnar nerve lacerations treated with direct repair or collagen conduit showed equivocal

results in nerve conduction studies and Rosen hand function scores at 2-year follow-up. Decellular nerve allografts have been shown to be an effective treatment for nerve gaps up to 3 cm, but larger randomized studies are needed to determine the efficacy compared with nerve autograft.<sup>27</sup>

### Neuroma Resection and Transposition Into Muscle

Nerve transposition into muscle was first described in 1918 by Moszkowicz who had "success" in 2 cases.<sup>11</sup> Mackinnon et al<sup>28</sup> showed that a sensory nerve implanted proximally into muscle had less scar formation in a primate model, and the nerve fibers were of smaller diameter and decreased density as compared with those left exposed in a wound. Dellon and Mackinnon<sup>8</sup> showed histologic and electron microscopic evidence that previous sensory neuromas transposed into muscles did not form a "classic neuroma," did not invade the muscle, and had less scar tissue than neuromas not confined by muscle. The goals of neuroma transposition into muscle include complete resection of the neuroma and transposition of the transected nerve end well away from an area that is subject to repeated trauma, movement, and

**Figure 5**

Zones of the hand to be used to guide relocation of end-neuromas in the hand and wrist.

mechanical stimulation. The implanted nerve end should be tension free and be placed in an area that will prevent regeneration into the skin and minimize the formation of scar tissue.<sup>9</sup> Transposition into a muscle with large excursion (abductor pollicis longus) or intrinsic hand muscles has been shown to be less effective than transposition into the pronator quadratus (PQ).<sup>9,22</sup> Other successful sites of neuroma resection and transposition in muscle include the PQ, brachioradialis, brachialis, biceps brachii, and triceps.<sup>7-9,22,29-31</sup> Good to excellent results are reported with neuroma resection and transposition into muscle and will be discussed further based on the zone of injury.<sup>1,7,8,30-33</sup> In all cases of neuroma resection and transposition, there will

be loss of distal sensation/function of the involved nerve.

### Neuroma Resection and Transposition Into Vein

Histologically, Koch et al<sup>34</sup> examined femoral nerve neuromas in a rat model that were resected and implanted into the femoral vein. Neuromas that underwent this treatment were smaller in size, had higher neural tissue to connective tissue ratios, and had a greater amount of organized fascicles compared with the control group, which underwent resection alone. With a clinical study, Koch et al<sup>33</sup> then followed 24 neuromas in 23 patients treated with neuroma excision and transposition into a vein with an average follow-up

of 26.5 months. Excellent or good results were found in 87% of patients with 12 patients having complete and permanent pain relief. With a mean follow-up of 15 months, Herbert and Filan<sup>35</sup> successfully treated 14 of 14 patients with neuromas with stump excision and transposition into a vein. Two patients who had persistent pain were reexplored and found that the nerve had pulled out of the vein; they were treated with the same technique and had “excellent results” at the final follow-up. A disadvantage of transposing a neuroma into a vein is that a painful neuroma can develop if the vein collapses or if nerve pulls away from the vein.<sup>22</sup>

### Surgical Management of Neuromas Based on Zones

Sood and Elliot<sup>7</sup> divided painful end-neuromas of the hand and wrist into three zones (Figure 5). Zone 1 neuromas are located distal to the metacarpal phalangeal joint and include digital nerves and terminal branches of nerves that provide sensation to the dorsum of the hand. Zone 2 neuromas include pain from the common digital nerves, the palmar cutaneous branches of the median and ulnar nerves, and dorsal branch of the ulnar nerve. Zone 3 neuromas comprise the radial border of the wrist and forearm, and they include pain from the SRN, lateral antebrachial cutaneous (LABC) nerve, medial antebrachial cutaneous (MABC) nerve, and posterior cutaneous nerve of the forearm (PCNF).

Several authors have suggested using the zones of the hand to help guide surgical relocation procedures for the neuromas. The first choice for relocation for zone 1 neuromas is the proximal phalanx or metacarpal; for zone 2, first choice of relocation is the PQ, and for zone 3 neuromas, it is recommended to relocate the neuroma to muscles of the arm and forearm, especially the brachioradialis.<sup>7,22,29-31,36</sup>

## Surgical Management of Zone 1 Neuromas

Zone 1 neuromas include all neuromas volar and dorsal to the metacarpal phalangeal joint. Amputation of the finger is the most common cause for digital neuromas, and it has been reported to occur in 2.7% to 30% of cases.<sup>1</sup> Van der Avoort et al<sup>1</sup> retrospectively reviewed 583 patients with a peripheral nerve injury and found that those with a digital amputation (177 patients) were more likely to develop a neuroma than those with a nerve injury without an amputation treated with primary nerve repair (7.3% versus 1%). Most procedures to treat zone 1 neuromas involve relocation of the nerve to a proximal site in bone or muscle. Hazari and Elliot<sup>36</sup> reported on 108 neuromas in zone 1 treated with proximal relocation; 98% of the relocated nerves had complete pain relief at the primary site, although 17% of the relocated nerves had pain at the site of relocation and 23% required more than one surgery. Their most common treatment was relocation of two bony segments proximal into the radial surface of the bone. If the neuroma was in the middle or proximal phalanx, the neuroma was taken through the interosseous muscle in the palm and relocated into a drill hole on the dorsoradial surface of the metacarpal. The authors recommended relocating two bony segments proximal to minimize trauma and to avoid any possible palmar-dorsal sensory nerve interconnections, which has been previously described and occurs most commonly at the middle of the proximal phalanx.<sup>37</sup>

Neuritis of the ulnar digital nerve of the thumb, also known as bowler thumb, is caused by abundant fibrous tissue formation around the nerve as a result of persistent compression or trauma, which infrequently forms a neuroma possibly from perineurium

damage and resultant fascicular escape.<sup>9,38</sup> In contrast to other zone 1 neuromas, bowler neuromas have been treated successfully with neurolysis and/or neurectomy and grafting. A recent case report successfully treated a bowler neuroma with transection of the adductor pollicis insertion followed by dorsal transposition of the ulnar digital nerve and subsequent reattachment of adductor pollicis volar to the transposed nerve. The patient returned to bowling at 5 months and had no recurrence of symptoms at 3-year follow-up.<sup>38</sup>

## Surgical Management of Zone 2 Neuromas

Neuromas of the common digital nerves, the palmar cutaneous branches of the median and ulnar nerves, and dorsal branch of the ulnar nerve compose zone 2. The PQ is one of the most commonly used muscles for implantation of a resected neuroma. This technique involves dissection and resection of the neuroma and the nerve proximally, with implantation into the PQ muscle at a depth of 0.5 cm.<sup>7</sup> Care must be taken to have sufficient length of the nerve, so that there is no tension with wrist or forearm range of motion. Evans and Dellon<sup>32</sup> had good to excellent results in 13 of 13 patients with end-neuromas of the palmar cutaneous branch of the median nerve that were implanted into the PQ at a mean follow-up of 19 months. Atherton et al<sup>30</sup> relocated 46 painful end-neuromas into the PQ; 31 of 46 relocated nerves had no pressure pain at the PQ, 12 nerves had mild pain with pressure, and 3 nerves had moderate pressure pain. With extremes of supination, pronation, and wrist extension, 10 nerves had mild pain and 7 nerves had moderate movement pain.

Sood and Elliot<sup>7</sup> reported on 13 painful neuromas in zone 2 that were treated with intraneural dissection of the neuroma and excision from its parent nerve followed by implantation

into the PQ. An intravenous cannula was placed proximal to the buried nerve, and 0.125% bupivacaine solution was infused continuously for 7 days. Pain to palpation of the neuroma was present in all cases before surgery and completely relieved post-operatively. Seventy percent of patients experienced some pain with palpation at the site of relocation, but all patients reported the new location was less frequently traumatized with routine use of the hand. Evans and Dellon<sup>32</sup> enrolled 13 consecutive patients with painful palmar cutaneous branch of the median nerve neuromas that were treated with resection of the neuroma and implantation into the PQ. At a mean follow-up of 19 months, 6 patients were graded as excellent and had no residual pain, had increased pinch/grip strength, and returned to previous work status. The remaining seven patients had minimal residual pain but worked at a new job capacity or had some degree of limitation of wrist movement and were graded as good.

## Surgical Management of Zone 3 Neuromas

Zone 3 neuromas encompass neuromas of the radial wrist and forearm and arise from the SRN, MABC, LABC, and PCNF.<sup>31</sup> Atherton et al<sup>31</sup> recommended transferring neuromas of the SRN to the brachioradialis muscle, neuromas of the LABC to the brachialis muscle above the elbow, neuromas of MABC to the biceps muscle above the elbow, and neuromas of the PCNF to the brachioradialis below the elbow or if proximal, into the triceps muscle. In their study of 33 patients, they reported on 51 painful end-neuromas in zone 3 arising from the SRN (29), LABC (16), MABC (2), and PCNF (4). All neuromas were excised and relocated proximally: 40 implanted into the brachioradialis, 3 implanted into the radius bone, and 1 into the flexor carpi radialis. Forty-seven of

51 nerves had total resolution of pain and hypersensitivity at the original neuroma site, 48 of 51 relocated nerves had no spontaneous pain at the relocation site, and 43 of 51 nerves had no pain on pressure at the relocation site. The authors warn that failure of relocation surgery in this zone may be secondary to incomplete “clearing” of the nerves involved; in a cadaver study, 75% of SRN and LABC had partial or complete overlap of cutaneous innervation. Secondary to the overlapping of sensory zones and possible interconnections between nerves, the authors recommended having a high suspicion for more than one involved nerve and dual neuroma excision and transposition when appropriate. Preoperative local anesthetic injections may help exclude a secondary nerve causing neuroma pain.

### Management of Neuromas Incontinuity

A neuroma-in-continuity is the result of an intact nerve being injured, which leads to dysfunction of the distal portion of the nerve as a result of internal damage of the fascicles. The supporting structure of the nerve remains intact; but, the damaged nerve fibers undergo degeneration, and a disorganized collection of nerve cells and connective tissue result at the injury site. Although altered, along with pain and hypersensitivity, neuroma-in-continuity may have some preserved sensory and motor function.<sup>3,36</sup> Hazari and Elliot<sup>36</sup> reported on 14 neuroma-in-continuity (9 following digital nerve microsurgical epineural repair and 5 following crush injuries to 3 digital nerves, 1 SRN, 1 dorsal branch of ulnar nerve) that were treated with resection and proximal relocation. When grouped with 83 other neuromas treated with proximal relocation, 77% were pain free at the final follow-up. For noncritical nerves, the authors recommend transecting the neuroma-in-continuity

and relocating proximally using the delineated techniques for a primary neuroma based on its location.

However, when preservation of the nerve is necessary for function (eg, median nerve at the carpal tunnel), resection and translocation of a neuroma-in-continuity would lead to poor results. Adani et al<sup>39</sup> treated nine median nerve neuroma-in-continuity at the level of the carpal tunnel with neurolysis and PQ muscle flap. At a mean follow-up of 23 months, eight of nine patients experienced pain relief, six patients had regression of the Tinel sign, and no patients were dissatisfied with their final results. Other authors use intraoperative neurophysiologic testing to decide if neurolysis alone or resection with grafting would lead to better outcomes. The question is whether the neuroma has the potential for further recovery before irreversible muscle damage sets in if the nerve in question is motor. If nerve stimulation proximal to the neuroma-in-continuity fails to evoke muscle contraction or a nerve action potential cannot be detected through the site in question, then resection of the neuroma to healthy fascicles and then reconstruction with nerve grafting is advocated.<sup>40</sup>

Digital nerve neuroma-in-continuity have had poor results with neuroma excision alone.<sup>21,22</sup> Thomsen et al<sup>25</sup> retrospectively reviewed 10 neuroma-in-continuity of the hand that underwent resection and repair with collagen tubes; all gaps were less than 20 mm. With a mean follow-up of 11.8 months, no patient had a reoccurrence of pain at the neuroma site. However, five patients continued to have cold intolerance, and only 50% had two-point discrimination less than 6 mm.

### Summary

Treating hand and wrist neuromas is a challenge with many treatment op-

tions. Careful history and physical examination are essential for correct diagnosis and management. Conservative options should be exhausted before any surgical intervention. Neuromas that fail this should then follow the three basic principles that were previously described for surgical management. Unfortunately, the literature does not clearly support one technique. For optimal outcomes, patients who undergo surgery should have signs and symptoms consistent with neuroma and pain in an anatomic distribution.

### References

*Evidence-based Medicine:* Levels of evidence are described in the table of contents. In this article, references 26 and 27 are level II studies. References 3, 9, 13, 17, 19, and 23 are level III studies. References 1, 2, 4, 6-8, 11, 12, 14-16, 18, 20-22, 24, 25, 28-37, and 39 are level IV studies. References 5, 10, 38, and 40 are level V studies.

References printed in **bold type** are those published within the past 5 years.

1. van der Avoort DJ, Hovius SE, Selles RW, van Neck JW, Coert JH: The incidence of symptomatic neuroma in amputation and neurotomy patients. *J Plast Reconstr Aesthet Surg* 2013;66:1330-1334.
2. Martins RS, Siqueira MG, Heise CO, Yeng LT, de Andrade DC, Teixeira MJ: Interdigital direct neurotomy for treatment of painful neuroma due to finger amputation. *Acta Neurochir (Wien)* 2015; 157:667-671.
3. Mavrogenis AF, Pavlakis K, Stamatoukou A, et al: Current treatment concepts for neuromas-in-continuity. *Injury* 2008; 39(suppl 3):S43-S48.
4. Stokvis A, van der Avoort DJ, van Neck JW, Hovius SE, Coert JH: Surgical management of neuroma pain: A prospective follow-up study. *Pain* 2010;151:862-869.
5. Sunderland S: The anatomy and physiology of nerve injury. *Muscle Nerve* 1990;13: 771-784.
6. Yuksel F, Kislaoğlu E, Durak N, Ucar C, Karacaoglu E: Prevention of painful neuromas by epineural ligatures, flaps and grafts. *Br J Plast Surg* 1997;50: 182-185.

7. Sood MK, Elliot D: Treatment of painful neuromas of the hand and wrist by relocation into the pronator quadratus muscle. *J Hand Surg Br* 1998;23:214-219.
8. Dellon AL, Mackinnon SE: Treatment of the painful neuroma by neuroma resection and muscle implantation. *Plast Reconstr Surg* 1986;77:427-438.
9. Watson J, Gonzalez M, Romero A, Kerns J: Neuromas of the hand and upper extremity. *J Hand Surg Am* 2010;35:499-510.
10. Novak CB, Mackinnon SE, Patterson GA: Evaluation of patients with thoracic outlet syndrome. *J Hand Surg Am* 1993;18:292-299.
11. Nath RK, Mackinnon SE: Management of neuromas in the hand. *Hand Clin* 1996;12:745-756.
12. Fisher GT, Boswick JA Jr: Neuroma formation following digital amputations. *J Trauma* 1983;23:136-142.
13. Wu J, Chiu DT: Painful neuromas: A review of treatment modalities. *Ann Plast Surg* 1999;43:661-667.
14. Ducic I, Mesbahi AN, Attinger CE, Graw K: The role of peripheral nerve surgery in the treatment of chronic pain associated with amputation stumps. *Plast Reconstr Surg* 2008;121:908-914.
15. Chu MM, Chan RK, Leung YC, Fung YK: Desensitization of finger tip injury. *Tech Hand Up Extrem Surg* 2001;5:63-70.
16. Laing T, Siddiqui A, Sood M: The management of neuropathic pain from neuromas in the upper limb: Surgical techniques and future directions. *Plast Aesthet Res* 2015;2:165.
17. Kesikburun S, Yasar E, Dede I, Goktepe S, Tan AK: Ultrasound-guided steroid injection in the treatment of stump neuroma: Pilot study. *J Back Musculoskelet Rehabil* 2014;27:275-279.
18. Rasmussen MR, Kitaoka HB, Patzer GL: Nonoperative treatment of plantar interdigital neuroma with a single corticosteroid injection. *Clin Orthop Relat Res* 1996;188-193.
19. Saarto T, Wiffen PJ: Antidepressants for neuropathic pain. *Cochrane Database Syst Rev* 2007:CD005454.
20. Carroll I: Pharmacologic management of upper extremity chronic nerve pain. *Hand Clin* 2016;32:51-61.
21. Tupper JW, Booth DM: Treatment of painful neuromas of sensory nerves in the hand: A comparison of traditional and newer methods. *J Hand Surg Am* 1976;1:144-151.
22. Guse DM, Moran SL: Outcomes of the surgical treatment of peripheral neuromas of the hand and forearm: A 25-year comparative outcome study. *Ann Plast Surg* 2013;71:654-658.
23. Tay SC, Teoh LC, Yong FC, Tan SH: The prevention of Neuroma formation by diathermy: An experimental study in the rat common peroneal nerve. *Ann Acad Med Singapore* 2005;34:362-368.
24. Al-Qattan MM: Prevention and treatment of painful neuromas of the superficial radial nerve by the end-to-side nerve repair concept: An experimental study and preliminary clinical experience. *Microsurgery* 2000;20:99-104.
25. Thomsen L, Bellemere P, Loubersac T, Gaisne E, Poirier P, Chaise F: Treatment by collagen conduit of painful post-traumatic neuromas of the sensitive digital nerve: A retrospective study of 10 cases. *Chir Main* 2010;29:255-262.
26. Weber RA, Breidenbach WC, Brown RE, Jabaley ME, Mass DP: A randomized prospective study of polyglycolic acid conduits for digital nerve reconstruction in humans. *Plast Reconstr Surg* 2000;106:1036-1045.
27. Boeckstyns ME, Sorensen AI, Vineta JF, et al: Collagen conduit versus microsurgical neurolysis: 2-year follow-up of a prospective, blinded clinical and electrophysiological multicenter randomized, controlled trial. *J Hand Surg Am* 2013;38:2405-2411.
28. Mackinnon SE, Dellon AL, Hudson AR, Hunter DA: Alteration of neuroma formation by manipulation of its microenvironment. *Plast Reconstr Surg* 1985;76:345-353.
29. Elliot D: Surgical management of painful peripheral nerves. *Clin Plast Surg* 2014;41:589-613.
30. Atherton DD, Leong JC, Anand P, Elliot D: Relocation of painful end neuromas and scarred nerves from the zone II territory of the hand. *J Hand Surg Eur Vol* 2007;32:38-44.
31. Atherton DD, Fabre J, Anand P, Elliot D: Relocation of painful neuromas in zone III of the hand and forearm. *J Hand Surg Eur Vol* 2008;33:155-162.
32. Evans GR, Dellon AL: Implantation of the palmar cutaneous branch of the median nerve into the pronator quadratus for treatment of painful neuroma. *J Hand Surg Am* 1994;19:203-206.
33. Koch H, Haas F, Hubmer M, Rappl T, Scharnagl E: Treatment of painful neuroma by resection and nerve stump transplantation into a vein. *Ann Plast Surg* 2003;51:45-50.
34. Koch H, Herbert TJ, Kleinert R, Hubmer M, Scharnagl E, Pierer G: Influence of nerve stump transplantation into a vein on neuroma formation. *Ann Plast Surg* 2003;50:354-360.
35. Herbert TJ, Filan SL: Vein implantation for treatment of painful cutaneous neuromas: A preliminary report. *J Hand Surg Br* 1998;23:220-224.
36. Hazari A, Elliot D: Treatment of end-neuromas, neuromas-in-continuity and scarred nerves of the digits by proximal relocation. *J Hand Surg Br* 2004;29:338-350.
37. Bas H, Kleinert JM: Anatomic variations in sensory innervation of the hand and digits. *J Hand Surg Am* 1999;24:1171-1184.
38. Swanson S, Macias LH, Smith AA: Treatment of bowler's neuroma with digital nerve translocation. *Hand (N Y)* 2009;4:323-326.
39. Adani R, Tarallo L, Battiston B, Marcoccio I: Management of neuromas in continuity of the median nerve with the pronator quadratus muscle flap. *Ann Plast Surg* 2002;48:35-40.
40. Kline DG, Nulsen FE: The neuroma in continuity: Its preoperative and operative management. *Surg Clin North Am* 1972;52:1189-1209.