CONTEMPORARY NEUROSURGERY

A BIWEEKLY PUBLICATION FOR CLINICAL NEUROSURGICAL CONTINUING MEDICAL EDUCATION

VOLUME 42 • NUMBER 18

December 30, 2020

Segmental Classification of the Internal Carotid Artery: An Overview

Sara Bonasia, MD, Alain Bouthillier, MD, and Thomas Robert, MD

Learning Objectives: *After participating in this CME activity, the neurosurgeon should be better be able to:*

1. *Define the internal carotid artery (ICA) segments and main branches.*
2. *Identify the most common ICA classifications.*
3. *Select the most helpful ICA classification for clinical practice.*

The internal carotid artery (ICA) is one of the most studied arteries in humans, as it interests a diverse group of physicians: ear, nose, and throat specialists; neuroradiologists; neurologists; anatomists; and neurosurgeons. During the past century, many classifications of the ICA segmental division have been proposed, with the purpose to be helpful during clinical practice. Because each specialist who treats pathologies of or around the ICA needs different details, a universally shared classification is difficult to propose. Historically, the classifications that spread the most had some important characteristics: simplicity, easy to use, easy to remember, and reproducibility. In this overview, we present the most used classifications of the ICA with their respective clinical implications, pros and cons, to help the reader to orientate and to choose the most helpful classification in his clinical practice.

History

The term "carotid" was already used by Greek physicians like Aristotle and Galen who, even with an incomplete idea of the human vascular circulation, understood the vital role of this vessel. After them, many physicians, anatomists, and humanists described their theories or hypotheses about the role of the carotid artery. These included Da Vinci (1504), Vesalius (1543), Harvey (1628), Willis (1664), and more recently Quain (1844), all of whom contributed to the knowledge of human vascular anatomy in their time.

In 1938, Fischer, a German anatomist, was the first to propose a classification of the segments of the ICA. However, only at the end of the 20th century, several authors became more interested in the ICA. Depending on the interest of each author, each classification was based on various elements. Lasjaunias (1984) described various segments based on their embryologic development to explain segmental agenesis of the ICA. In the same period, on the one hand Gibo and Rhoton and on the other Bouthillier proposed their classification principally basing on the surgical anatomy of the artery. On the other hand, surgeons experienced in endonasal surgery proposed some classifications focused on the cavernous and petrous segments of the carotid artery.

Fischer's Classification

In 1938, Erich Fischer proposed the first segmental classification concerning the ICA and also its 2 major branches: the anterior and middle cerebral arteries. In its classification,

Dr. Bonasia is a Resident, Department of Neurosurgery, Neurocenter of the Southern Switzerland, Lugano, Switzerland; Dr. Bouthillier is Neurosurgeon, Division of Neurosurgery, University of Montreal Hospital Center (CHUM), Montreal, Quebec, Canada; and Dr. Robert is Neurosurgeon, Department of Neurosurgery, Neurocenter of the Southern Switzerland, Via Tesserete 46, 6903 Lugano (TI), Switzerland; E-mail: sara.bonasia@gmail.com.

The authors, faculty, and staff in a position to control the content of this CME activity, and their spouses/life partners (if any), have disclosed that they have no financial relationships with, or financial interests in, any commercial organizations relevant to this CME activity.

Category: Cerebrovascular

Key Words: Internal carotid artery, Segments of the internal carotid artery

Lippincott Continuing Medical Education Institute, Inc., is accredited by the Accreditation Council for Continuing Medical Education to provide continuing medical education for physicians.

Lippincott Continuing Medical Education Institute, Inc., designates this enduring material for a maximum of 2.0 *AMA PRA Category 1 Credits*™. Physicians should claim only the credit commensurate with the extent of their participation in the activity. To earn CME credit, you must read the CME article and complete the quiz and evaluation on the enclosed form, answering at least 70% of the quiz questions correctly. This activity expires on December 29, 2022.

the ICA segments are numbered following the opposite direction of the blood flow. Fischer did not consider the anatomic relationship of the artery but segmented the ICA depending on the different arterial displacement in extrinsic tumoral compression. This classification was based on angiographic studies. From its termination to its cavernous region, the ICA was segmented into 5 different segments (Figure 1):

1. The first segment (C1) is the portion of the ICA from its termination to the origin of the posterior communicating artery.
2. The second segment (C2) is the part of the ICA between the origin of the posterior communicating artery and the origin of the ophthalmic artery (OA).
3. The third segment (C3) is the anterior genu of the ICA that corresponds to the clinoidal portion of the artery.
4. The fourth segment (C4) is the cavernous portion of the artery that ends at the posterior genu of the ICA.
5. The fifth segment (C5) is the part of the ICA lateroinferior to the cavernous sinus in the lacerum foramen. This segment does not include the petrous segment.

This classification has the merit to be the first one and to have helped physicians understand tumor location before the CT era. The disadvantages of this classification were the numbering opposite to the arterial flow, the exclusion of the petrous and cervical portions of the artery, and the absence of correspondence to anatomic landmarks. In 1994, Fukushima, in a personal communication, proposed a change of this classical classification, adding a sixth segment (C6F) that corresponds to the petrous portion of the artery.

Gibo and Rhoton's Classification

This classification, proposed in 1981, is actually the most used. It was proposed after the cadaveric dissection of 25 brains. This is the first anterograde segmentation of the ICA. Each segment of the artery has a different anatomic compartment that makes this classification easy to use and reproducible. The various segments are illustrated in Figure 2 and described as follows:

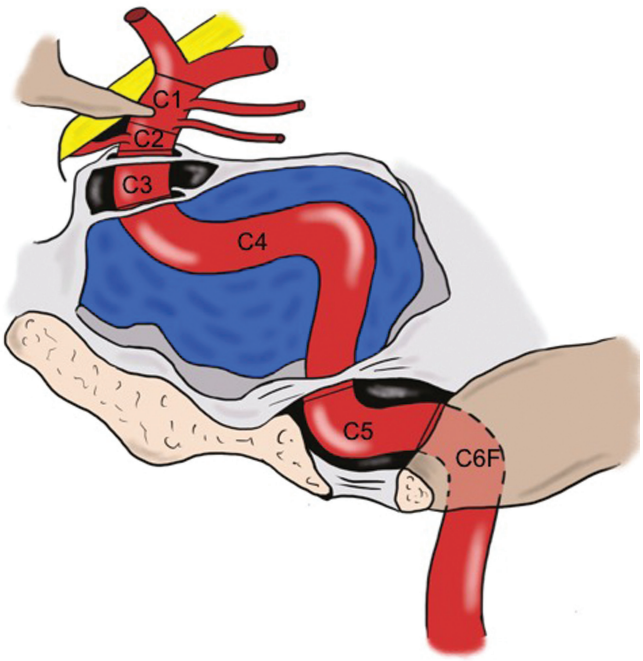

Figure 1. Fischer's classification.

1. C1 is the cervical portion of the ICA from its origin to its entry into the external orifice of the carotid canal.
2. C2 is the petrous portion of the artery from the external orifice of the carotid canal to the entry of the ICA into the cavernous sinus.
3. C3 corresponds to the cavernous portion of the artery from its entrance in the posterior part of the cavernous sinus to its exit near the anterior clinoidal process. The origin of the OA is assimilated to the junction between C3 and C4 (cavernous and supraclinoid) segments.

The continuing education activity in *Contemporary Neurosurgery* is intended for neurosurgeons, neurologists, neuroradiologists, and neuropathologists.

Contemporary Neurosurgery (ISSN 0163-2108) is published bi-weekly by Wolters Kluwer Health, Inc. at 14700 Citicorp Drive, Bldg 3, Hagerstown, MD 21742. **Customer Service: Phone (800) 638-3030, Fax (301) 223-2400, or E-mail customerservice@lww.com.** Visit our website at www.lww.com.

Wolters Kluwer

 Priority Postage paid at Hagerstown, MD, and at additional mailing offices. POSTMASTER: Send address changes to Contemporary Neurosurgery, Subscription Dept., Wolters Kluwer, P.O. Box 1610, Hagerstown, MD 21740.

Publisher: John Ewers

Subscription rates: *Individual*: US $891, international $1247. *Institutional*: US $1519, international $1569. *In training:* US $164, international $165. Single copies: $85. GST Registration Number: 895524239. Send bulk pricing requests to Publisher.

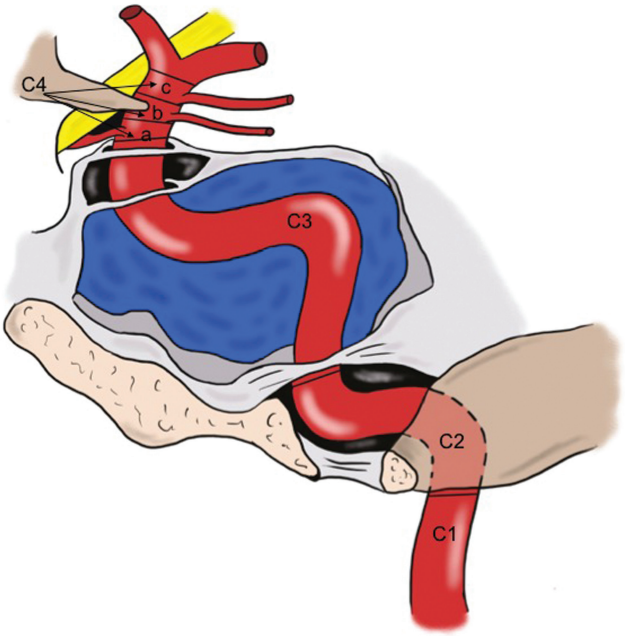

Figure 2. Rhoton's classification.

4. C4 is the supraclinoid portion of the ICA that was divided by Gibo et al. in 3 distinct parts: the ophthalmic segment (C4-a) from the origin of the OA to the origin of the posterior communicating artery, the communicating part (C4-b) from the origin of the posterior communicating artery to the origin of the anterior choroidal artery, and the choroidal part (C4-c) from the origin of the anterior choroidal artery to the ICA bifurcation.

This classification highlights the precise anatomy of perforating arteries from the ICA on its supraclinoid portion and was oriented in the surgical clipping of ICA aneurysms with precise description of anatomic relationship between aneurysmal sac and perforating arteries.

Embryologic Classification (Lasjaunias)

This classification was first proposed by Lasjaunias and Santoyo-Vasquez in 1984 and is based only on embryologic knowledge of the carotid artery system. The aim of this classification is to explain and understand the various types of segmental agenesis and other anatomic variations encountered in the clinical practice. ICA development depends on the third aortic arch and on the dorsal aorta cranial to the third aortic arch. During the embryologic life, the ICA gives origin to different branches that delimitate various segments of this classification. The embryologic segments of the ICA and their corresponding segments in the adult are summarized in Table 1.

It is important to remember that, from an embryologic standpoint, the ICA bifurcates in 2 cranial and caudal divisions that correspond to the future anterior cerebral artery and to the future posterior communicating artery.

According to Lasjaunias and Santoyo-Vasquez (1984), the various segments of the ICA (Figure 3) can be identified as follows:

1. The first segment corresponds to the third aortic arch from the origin of the ventral pharyngeal artery (future external carotid artery) to the junction between the third aortic arch and the dorsal aorta. In the adult, it corresponds to the cervical ICA.
2. The second segment is the dorsal aorta between the second and third aortic arches. Its distal part is the hyoid artery in the embryo and the caroticotympanic artery in the adult (ascending intrapetrous segment).
3. The third segment is the dorsal aorta between the second and first aortic arches. It corresponds in the embryo to the segment between the hyoid and the mandibular artery, and, in the adult, between the caroticotympanic artery and the vidian artery (horizontal intrapetrous segment).
4. The fourth segment is the dorsal aorta between the first aortic arch (future mandibular artery) and the origin of the trigeminal artery (and the primitive maxillary artery). In the adult, it corresponds to the segment between the vidian artery and the origin of the meningohypophyseal trunk (ascending foramen lacerum segment).
5. The fifth segment is the dorsal aorta between the origin of the trigeminal artery (and the primitive maxillary artery) and the origin of the primitive dorsal ophthalmic artery (PDOA, future inferolateral trunk—ILT). It corresponds in the adult to the horizontal cavernous segment between the meningohypophyseal and inferolateral trunks.
6. The sixth segment is between the origin of the PDOA and the anastomotic point of the primitive ventral ophthalmic artery (PVOA) on the ICA. This segment in the adult is the clinoid segment between the origin of the ILT and the OA.
7. The seventh segment is between the anastomotic point of the PVOA and the primitive carotid bifurcation. In the

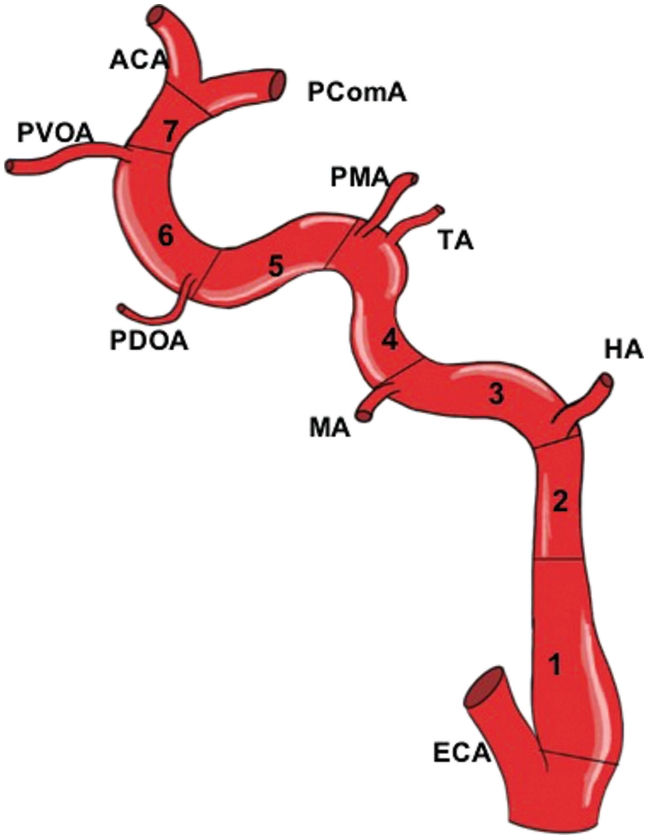

Figure 3. Lasjaunias' classification.

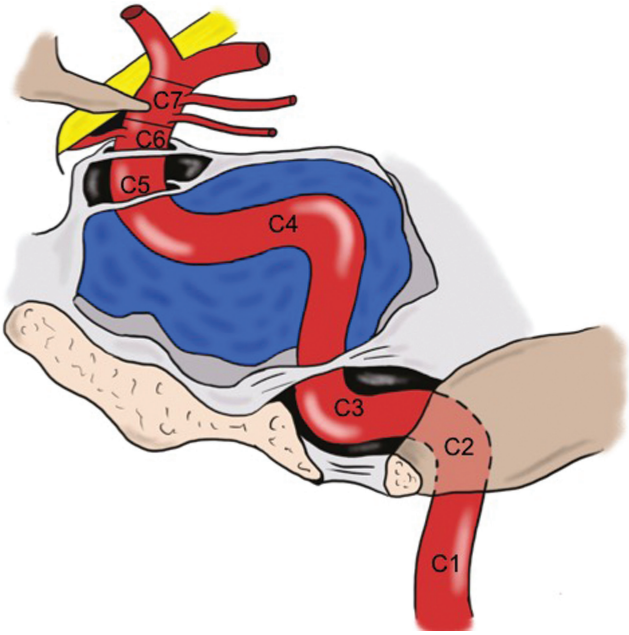

Figure 4. Bouthillier's classification.

adult, this is the supraclinoid ICA from the origin of the OA to the origin of the posterior communicating artery.

It is important to note that the carotid bulb has not the same embryologic origin than the other segments of the ICA. It originates from the pharyngo-occipital system that easily explains variations in origin of the ascending pharyngeal and occipital arteries.

This classification allows to understand and explain quite all forms of agenesis and variations of the ICA and is based on 2 fundamental principles. First, each segment is considered to have a distinct embryologic development; second, the agenesis of one segment of the ICA leads to the regression of all segments proximal to the anomaly.

However, in 2004, Gailloud presented a case of ICA agenesis distal to the posterior communicating artery origin. Consequently, he discussed the presence of an eighth embryologic ICA segment. This hypothesis was clearly refused by P. Lasjaunias, who considered the adult ICA distal to the posterior communicating artery origin not as an ICA segment.

Bouthillier's Classification

In 1996, Bouthillier et al. proposed another segmental classification (Figure 4) based on a cadaveric study of 10 specimens. They divided the petrous segment in petrous and lacerum segments because they observed that, in this lacerum segment, the carotid artery is not completely englobed into the petrous bone but into a dural ligament. They argued this added segment for its clinical implication for surgical approaches of Meckel's cave. They also added the clinoidal segment that is the little part of the ICA between the proximal and distal dural rings.

Consequently, in Bouthillier's classification, the ICA is segmented in 7 portions:

1. The cervical segment (C1) from the carotid bifurcation to the external extremity of the carotid canal.
2. The petrous segment (C2) from the external orifice of the carotid canal to the posterior edge of the foramen lacerum.
3. The lacerum segment (C3) extends from the end of the carotid canal (posterior edge of the foramen lacerum) to the entry point of the carotid artery into the cavernous sinus. In this portion, the petrolingual ligament only covers the carotid artery.

Table 1. Embryologic Segments of the ICA With Their Corresponding Segments in the Adult

Embryologic Segment	Embryologic Origin	Adult Segment	Proximal Limit	Distal limit
First	Third aortic arch	Cervical ICA	Carotid bulb	Junction cervical-petrous ICA
Second	Dorsal aorta Between the second and third aortic arches	Ascending petrous segment	Junction cervical-petrous ICA	Caroticotympanic artery
Third	Dorsal aorta Between the first and second aortic arches	Horizontal petrous segment	Caroticotympanic artery	Vidian artery
Fourth	Dorsal aorta Between the first aortic arch and the primitive maxillary artery	Ascending lacerum segment	Vidian artery	Meningohypophyseal trunk
Fifth	Dorsal aorta Between the primitive maxillary artery and the PDOA	Horizontal cavernous segment	Meningohypophyseal trunk	Inferolateral trunk
Sixth	Dorsal aorta Between the PDOA and the PVOA	Clinoidal segment	Inferolateral trunk	Ophthalmic artery
Seventh	Dorsal aorta Distal to the PVOA	Ophthalmic segment	Ophthalmic artery	Posterior communicating artery

ICA, internal carotid artery; PDOA, primitive dorsal ophthalmic artery; PVOA, primitive ventral ophthalmic artery.

Table 2. Summary of the Various Classifications About the Internal Carotid Artery

ICA Classification	Fischer	Lasjaunias	Gibo-Rhoton	Bouthilier	Ziyal	Shapiro	Abdulrauf
Cervical	x	1	C1	C1	C1	Cervical	x
Petrous	C6 (added by Fukushima)	2 and 3	C2	C2-C3	C2	Petrous	Cochlear petrous clival
Cavernous	C4-C5	4 and 5	C3	C4	C3	Cavernous	Sellar
Clinoidal	C3	6	C3	C5	C4	Periophthalmic	Sphenoid
Ophthalmic	C2	7	C4-opht	C6	C5	Periophthalmic	Cisternal
Communicating	C1	x	C4-com	C7	C5	Communicating	Cisternal
Choroidal	C1	x	C4-chor	C7	C5	Choroidal and terminus	Cisternal

ICA, internal carotid artery.

4. The cavernous portion (C4) begins at the entry point of the carotid artery into the cavernous sinus and ends at the exit point of the artery at the level of the inferior dural ring of the anterior clinoid process.
5. The clinoid segment (C5) extends from the inferior to the superior dural rings. In this segment, the carotid artery is in a fibro-osseous canal before entering into the subarachnoidal compartment.
6. The ophthalmic segment (C6) begins at the distal dural ring and ends just proximal to the origin of the posterior communicating artery.
7. The communicating segment (C7) is the distal portion of the ICA from the origin of the posterior communicating artery to its bifurcation.

Other Classification Systems

Recently, numerous authors have proposed various classification depending on their specialty and their interest in their respective clinical practices. The most interesting classifications are summarized in Table 2. Ziyal et al. (2005) proposed an anatomic classification based on cadaveric dissections of 15 human heads. In this classification, authors highlighted the importance of the clinoidal segment, as described by Bouthillier et al. 10 years before. This classification is helpful for skull base surgeons in case of surgical procedures of the cavernous sinus or in case of anterior clinoidectomy. Shapiro et al. (2014) proposed another classification of the ICA in 7 segments without differentiation between clinoidal and ophthalmic segments but adding a terminal segment distal to the choroidal segment. This classification was made regarding various possible locations of ICA aneurysms and depending on choice of endovascular technique. Other than a segmental classification, Abdulrauf et al. published a study focused on various angles and curvature of the ICA. This description is helpful for endoscopic surgeons to avoid vascular damage during these approaches. Similarly, Wang et al. gave a precise description of the shape and curvature of the ICA in its cavernous segment to help identify it during transsphenoidal surgery.

Conclusion

Each of these classifications brings important information about the anatomy of the ICA and finds their utility in clinical practice. Depending on the specialty of each physician, one of these classifications may be more useful than another. For example, anatomists and neurosurgeons often use the classification of Gibo et al. or the classification of Bouthillier et al., which are the 2 most "anatomic" classifications. Knowledge of the history and the major classifications is important so that physicians have the same language to define the ICA.

Readings

Abdulrauf SI, Ashour AM, Marvin E, et al. Proposed clinical internal carotid artery classification system. *J Craniovertebr Junction Spine*. 2016;7(3):161-170.

Altmann F. Anomalies of the internal carotid artery and its branches; their embryological and comparative anatomical significance; report of a new case of persistent stapedial artery in man. *Laryngoscope*. 1947;57(5):313-339.

Bouthillier A, van Loveren HR, Keller JT. Segments of the internal carotid artery: a new classification. *Neurosurgery*. 1996;38(3):425-432; discussion 432-433.

Dungan DH, Heiserman JE. The carotid artery: embryology, normal anatomy, and physiology. *Neuroimaging Clin N Am*. 1996;6(4):789-799.

Gailloud P, Clatterbuck RE, Fasel JH, et al. Segmental agenesis of the internal carotid artery distal to the posterior communicating artery leading to the definition of a new embryologic segment. *AJNR Am J Neuroradiol*. 2004;25(7):1189-1193.

Lasjaunias P, Bereinstein A, Ter Brugge KG. *Surgical Neuroangiography*. Vol 1. Berlin, Germany: Springer Edition; 2001.

Lasjaunias P, Santoyo-Vazquez A. Segmental agenesis of the internal carotid artery: angiographic aspects with embryological discussion. *Anat Clin*. 1984;6(2):133-141.

Mele MV, Puigdellivol-Sanchez A, Mavar-Haramija M, et al. Review of the main surgical and angiographic-oriented classifications of the course of the internal carotid artery through a novel interactive 3D model. *Neurosurg Rev*. 2020;43(2):473-482.

Rhoton AL Jr. The supratentorial arteries. *Neurosurgery*. 2002;51(4 suppl): S53-S120.

Shapiro M, Becske T, Riina HA, et al. Toward an endovascular internal carotid artery classification system. *AJNR Am J Neuroradiol*. 2014;35(2):230-236.

Wang C, Xie J, Cui D, et al. A new classification of cavernous segment of the internal carotid artery. *J Craniofac Surg*. 2013;24(4):1418-1422.

Ziyal IM, Ozgen T, Sekhar LN, Ozcan OE, Cekirge S. Proposed classification of segments of the internal carotid artery: anatomical study with angiographical interpretation. *Neurologia Medico-chirurgica*. 2005; 45(4):184-190.

To earn CME credit, you must read the CME article and complete the quiz and evaluation on the enclosed form, answering at least 70% of the quiz questions correctly. **Select the best answer and use a blue or black pen to completely fill in the corresponding box on the enclosed answer form.** Please indicate any name and address changes directly on the answer form. If your name and address do not appear on the answer form, please print that information in the blank space at the top left of the page. Make a photocopy of the completed answer form for your own files and mail the original answer form in the enclosed postage-paid business reply envelope. Your answer form must be received by Lippincott CME Institute, Inc., by **December 29, 2022.** Only two entries will be considered for credit. For more information, call (800) 638-3030.

Online quiz instructions: To take the quiz online, **log on to your account** at **www.contempneurosurg.com**, and click on the "CME" tab at the top of the page. Then click on "Access the CME activity for this newsletter," which will take you to the log-in page for **http://cme.lww.com**. Enter your *username* and *password*. Follow the instructions on the site. You may print your official certificate ***immediately.*** Please note: Lippincott CME Institute, Inc., **will not** mail certificates to online participants. **Online quizzes expire on the due date**.

The American Association of Neurological Surgeons (AANS) manually tracks *AMA PRA Category 1 Credits*™ earned from neurosurgery activities not sponsored or joint-sponsored by the AANS. As a service to AANS members, Lippincott CME Institute will continue to provide the AANS a monthly listing of their participants and the CME credits they earned so that AANS members do not have to send their individual certificates to the AANS for tracking.

1. According to Fischer's classification, the ICA segments are numbered following the blood flow direction.

True or False?

2. Fischer's classification is based on different arterial displacement in extrinsic tumoral compression.

True or False?

3. Rhoton's classification divides the ICA by referring to precise anatomic landmarks.

True or False?

4. In Rhoton's classification, the supraclinoid portion is divided into 3 parts to provide a more specific division of the perforating arteries that can be encountered during anterior circulation aneurysm clipping.

True or False?

5. The classification of Lasjaunias is based on ICA surgical anatomy.

True or False?

6. According to Lasjaunias' concept, each ICA segment has a distinct embryologic development, and the agenesis of one of them leads to the regression of all of the segments proximal to the anomaly.

True or False?

7. Figure 5 shows a left ICA angiogram, in which the ICA is divided according to Bouthillier's classification.

True or False?

8. The *blue star* in Figure 5 indicates the petrous segment of the ICA, according to Bouthillier's classification.

True or False?

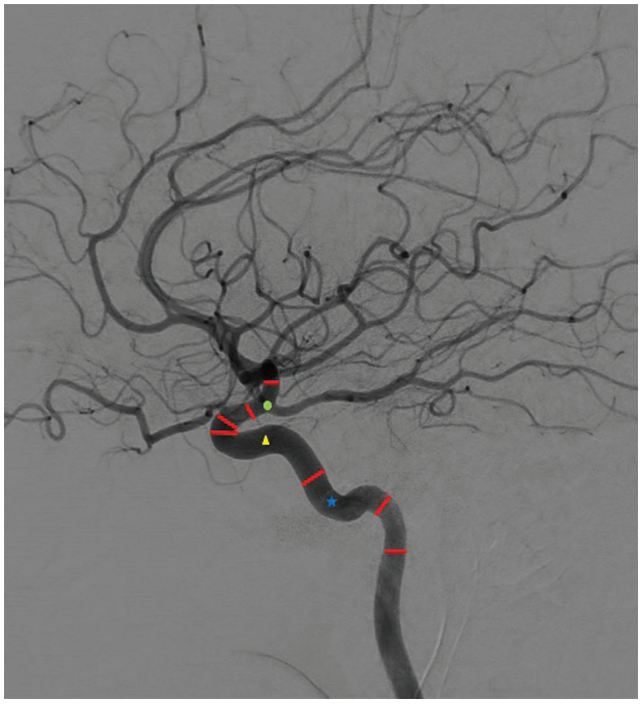

Figure 5.

9. The *yellow triangle* in Figure 5 represents the petrous segment of Bouthillier's classification.

True or False?

10. The *green circle* in Figure 5 indicates the communicant segment of Bouthillier's classification and is located at the origin of the anterior choroidal artery.

True or False?