

Management of Trauma to the Rectum and Anus

Lawrence Lee, M.D., Ph.D. • Katherine M. McKendy, M.D., M.Ed.

Department of Surgery, McGill University Health Centre, Montreal, Quebec

CASE SUMMARY: A 27-year-old woman was brought to the emergency department with multiple penetrating injuries to her gluteal and perineal areas. On primary survey, she was hemodynamically normal without signs of peritonitis. Her secondary survey demonstrated deep left gluteal laceration with small bowel eviscerating through this defect, as well as another smaller defect on the right perianal verge. She was brought to the operating room for exploratory laparotomy and examination of her perineal wounds under anesthesia. On laparotomy, the small bowel could be seen herniating through a defect in the left mesorectum extending through the pelvic floor, gluteus, and piriformis. A small-bowel perforation with intestinal spillage was identified that required resection and primary anastomosis. She also had combined intra- and extraperitoneal full-thickness nondestructive rectal injuries (Fig. 1). She underwent primary repair of her intra- and extraperitoneal rectal injuries, reapproximation of the peritoneum at the mesorectal defect to prevent further herniation, and proximal diversion with a sigmoid loop colostomy. Distal rectal washout and presacral drainage were not performed.

CLINICAL QUESTIONS

- Is proximal diversion necessary in rectal trauma?
- Should presacral drainage and rectal washout be performed for extraperitoneal rectal injuries?
- Should immediate primary repair be attempted for traumatic sphincter injuries?



Earn Continuing Medical Education (CME) credit online at cme.lww.com. This activity has been approved for AMA PRA Category 1 credit™.

Funding/Support: None reported.

Financial Disclosures: Dr Lee is the recipient of an unrestricted educational grant from Johnson & Johnson.

Correspondence: Lawrence Lee, M.D., Ph.D., 1001 Decarie Blvd, DS1-3310, Montreal, QC H4A 3J. E-mail: larry.lee@mcgill.ca

Dis Colon Rectum 2018; 61: 1245–1249

DOI: 10.1097/DCR.0000000000001221

© The ASCRS 2018

DISEASES OF THE COLON & RECTUM VOLUME 61: 11 (2018)

BACKGROUND

The management of traumatic injuries to the lower GI tract has evolved from experiences in the military setting. Traditionally, damage control principles (the 4 Ds: diversion, distal rectal washout, drainage of the presacral area, and direct repair) have guided management and have led to a significant decrease in infectious complications and mortality.¹ However, there are important differences in the injury patterns that occur in the military and civilian settings; military injuries tend to be from high-velocity gunshot wounds or blunt force from blast injuries (Fig. 2), whereas civilian injuries arise predominantly from penetrating low-velocity missiles. Given these differences, it is unclear whether civilian trauma should be managed in the same manner as wartime injuries. This

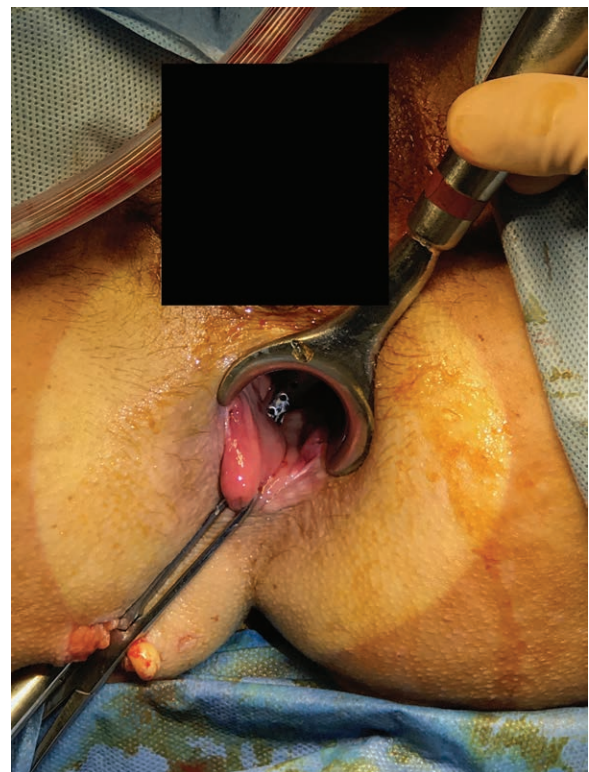


FIGURE 1. Penetrating transgluteal full-thickness injury to the extraperitoneal rectum.

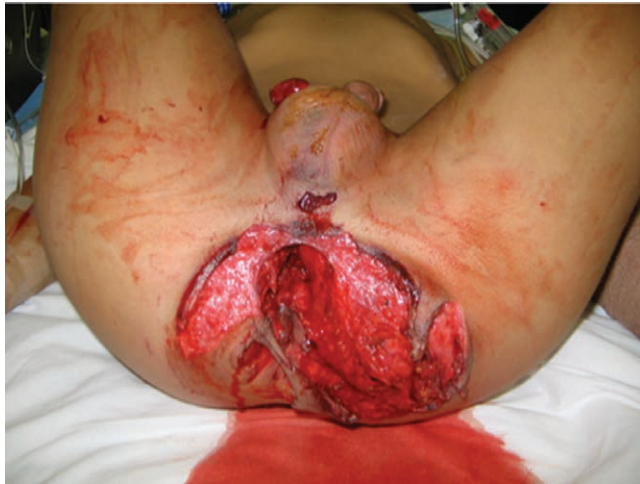

FIGURE 2. Blast injury to the perineum requiring diverting colostomy. Photo courtesy of Dr Brian Perry, University of Texas Health Science Center at San Antonio.

review will cover the current recommendations for the management of trauma to the intra- and extraperitoneal rectum and anus.

INITIAL EVALUATION

The initial evaluation of any trauma patient should follow Advanced Trauma Life Support principles, beginning with the primary survey to identify and stabilize immediate life-threatening injuries. Suspected anorectal injuries are assessed during the secondary survey. A more detailed history should be obtained when possible, including baseline fecal continence. Patients with anorectal trauma have a high incidence of concomitant injuries,² and understanding the mechanism of trauma can help identify these. Although digital rectal examination is a mandatory element of the Advanced Trauma Life Support secondary survey, its value to detect rectal injuries is limited.³ Rather, further investigation with rigid proctoscopy or sigmoidoscopy should be performed if an anorectal injury is suspected based on mechanism and physical examination, although care must be taken to not further worsen the injury. This should be done in the operating room if additional intervention is required. Computed tomography has limited value in specifically detecting anorectal injuries, but may provide additional information regarding peritoneal violation. In penetrating trauma, triple contrast (intravenous, oral and rectal) can be used to increase the sensitivity of the examination and allow for further evaluation of the retroperitoneum.

Rectal injuries are classified according to the American Association for the Surgery of Trauma (AAST) Rectum Injury Scale (Table 1). However, the operative decision making depends more on the hemodynamic stability of the patient, need for transfusion and volume resuscitation,

TABLE 1. Rectum Injury Scale from the American Association for the Surgery of Trauma (AAST)

Grade ^a	Type of injury	Description of injury
Ia	Hematoma	Contusion or hematoma without devascularization
Ib	Laceration	Partial-thickness laceration
II	Laceration	Laceration <50% circumference
III	Laceration	Laceration ≥50% circumference
IV	Laceration	Full-thickness laceration with extension into the perineum
V	Vascular	Devascularized segment

^aAdvance 1 grade for multiple injuries up to grade III.

presence of other injuries, degree of fecal contamination, and the location of the injury (intra- versus extraperitoneal), than the specific AAST grade of injury.

MANAGEMENT

Intraperitoneal Rectal Injuries

Intraperitoneal rectal injuries can be treated in the same manner as colonic injuries. For stable patients, there are level I data to support primary repair of nondestructive injuries without significant fecal contamination that involve less than 50% of the circumference of the colon.⁴ In cases where a primary repair is not feasible, a segmental resection and primary anastomosis can be performed with low morbidity. The use of a diverting colostomy is not generally required. In an AAST multi-institutional cohort study of level I trauma centers in the United States, patients managed with diversion had more abdominal complications with no difference in mortality.² Unstable patients should be managed according to damage control principles with control of contamination and delay of definitive management (diversion or anastomosis) until the patient is stabilized. However, patients managed initially with open abdomen may be at higher risk of anastomotic leak, even when the anastomosis is created in a delayed manner under more optimal conditions.⁵ Patients should be carefully selected (<6 units transfusion requirement and without significant comorbidities) for delayed anastomosis in this setting.⁶

Extraperitoneal Rectal Injuries

In contrast to intraperitoneal injuries, all full-thickness lacerations to the extraperitoneal rectum should be managed with a diverting stoma. Published experience with primary repair of an extraperitoneal rectal injury without proximal diversion is minimal.⁷ Although there does not appear to be a difference in mortality between proximal diversion versus primary repair without diversion, the incidence of infectious complications is decreased by 50% with diversion.⁸ In the presence of a diverting stoma, primary repair of the rectal injury is not neces-

sary but can be performed if it can be easily accessed.⁸ Recent developments in transanal endoscopic surgery techniques may allow for closure of more proximal extraperitoneal injuries,⁹ although it is not clear whether this will ultimately affect outcomes. Antibiotic therapy should cover enteric flora and continue for at least 24 hours after surgery.

The main areas of controversy in the management of extraperitoneal rectal injuries involve the necessity of a distal rectal washout and presacral drainage. Distal rectal washout was initially popularized during the Vietnam War, but some have hypothesized that its benefit during this conflict was due to the pattern of injuries seen (which are generally different from the civilian setting), as well as the limited antibiotic regimens available during that time. This practice, in general, has fallen out of favor because there are concerns about the possibility of worsening the rectal injury. There is no clear evidence to demonstrate improvements in mortality or infectious complications between patients undergoing distal rectal washout and those that did not, resulting in a conditional recommendation against its use.⁸

Similarly, the use of presacral drainage has also begun to fall out of favor. The placement of a presacral drain requires significant dissection and disruption of normal tissue if the injury has not already done so. Analysis of the available data suggests that both mortality and infectious complications are higher in patients undergoing presacral drainage, although this may be due to selection bias. The single randomized trial conducted on the topic included 48 patients and did not identify any difference in complications between the drain and no-drain groups; this trial may have been underpowered to detect a true difference.¹⁰ In the presence of these data, the Eastern Association for the Surgery of Trauma guidelines conditionally recommend against the use of presacral drains.⁸ In the same AAST multi-institutional study, both distal rectal washout and presacral drainage were independently associated with increased complications regardless of injury severity or mechanism.²

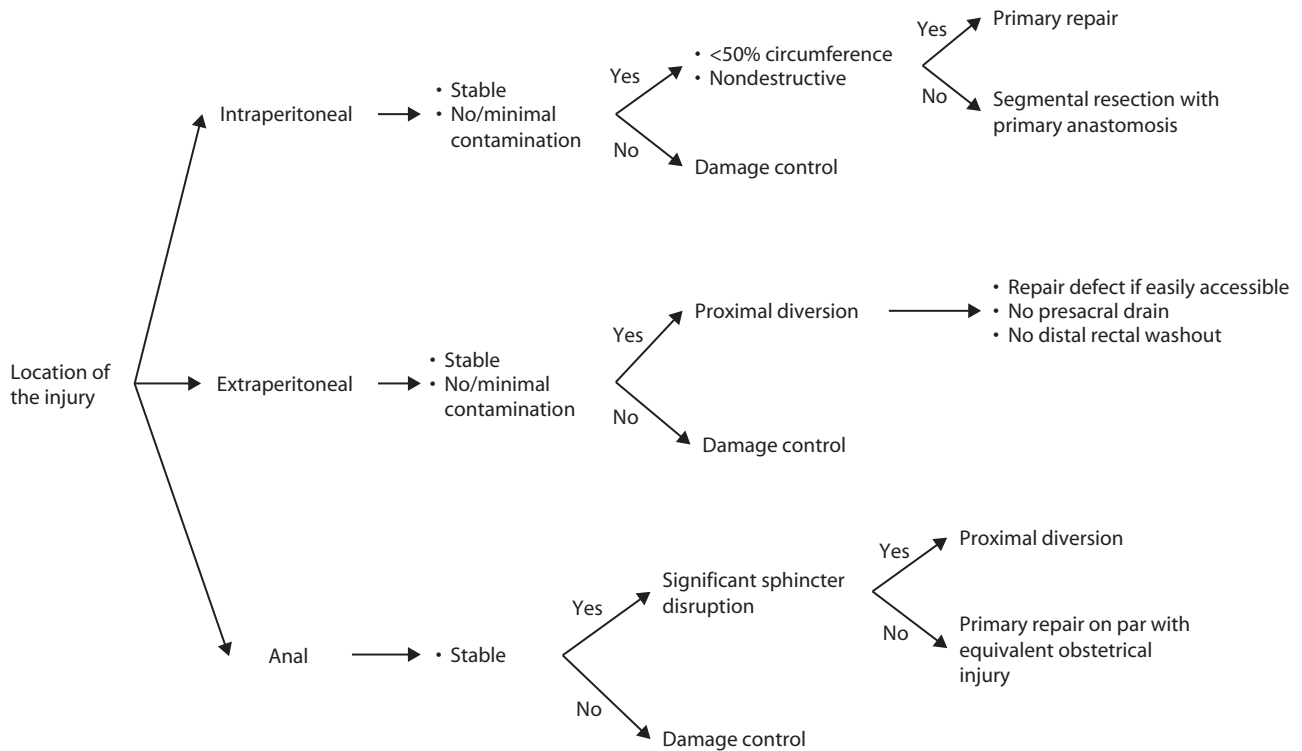
Anal Sphincter Injuries

There are very limited data to guide the management of patients with traumatic injuries to the anal sphincter.⁷ There is a high incidence of concomitant injuries to the rectum, associated intra-abdominal and pelvic injuries, or perineal soft-tissue damage. In 1 study of 46 military anal injuries (mostly blast mechanisms with a high incidence of other severe intra-abdominal and pelvic injuries), acute anal sphincter repair was attempted in 11 patients (with 9 patients undergoing concomitant proximal diversion), but did not influence the need for permanent colostomy rates.¹¹ Older studies have shown good functional outcomes with delayed sphincter repair.¹² Based on these data, the value of acute sphincter repair after traumatic disruption is questionable, and patients should be managed with proximal diversion in the setting of significant sphincter injury. If possible, the disrupted sphincter muscle ends can be tagged to minimize retraction and facilitate future repair. Anorectal manometry can be performed before colostomy reversal and has been shown to predict functional outcome.¹² The long-term outcomes of acute traumatic sphincter repair are unknown.

CONCLUSIONS

The management of anorectal trauma is complex, and often requires the simultaneous management of other serious traumatic injuries. Once life-threatening injuries have been controlled, the main goal of treatment of anorectal injuries is to minimize infectious complications, which carry a high mortality rate. We have conducted a review of the literature to answer our clinical questions stated above. Proximal diversion remains the mainstay of the management of extraperitoneal rectal injuries, whereas presacral drainage and rectal washout have fallen out of favor and may result in increased harm. For intraperitoneal injuries, diversion is only necessary in the case of extensive injuries or significant fecal contamination. With regard to sphincter injuries, few data are available to guide management. The management of rectal injuries continues to evolve and improve, but further data would help determine how best to manage these complicated cases.

EVALUATION AND TREATMENT ALGORITHM



REFERENCES

1. Lavenson GS, Cohen A. Management of rectal injuries. *Am J Surg*. 1971;122:226–230.
2. Brown CVR, Teixeira PG, Furay E, et al; AAST Contemporary Management of Rectal Injuries Study Group. Contemporary management of rectal injuries at level I trauma centers: the results of an American Association for the Surgery of Trauma multi-institutional study. *J Trauma Acute Care Surg*. 2018;84:225–233.
3. Esposito TJ, Ingraham A, Luchette FA, et al. Reasons to omit digital rectal exam in trauma patients: no fingers, no rectum, no useful additional information. *J Trauma*. 2005;59:1314–1319.
4. Pasquale M, Fabian TC. Practice management guidelines for trauma from the Eastern Association for the Surgery of Trauma. *J Trauma*. 1998;44:941–956.
5. Ott MM, Norris PR, Diaz JJ, et al. Colon anastomosis after damage control laparotomy: recommendations from 174 trauma colectomies. *J Trauma*. 2011;70:595–602.
6. Sharpe JP, Magnotti LJ, Weinberg JA, et al. Applicability of an established management algorithm for destructive colon injuries after abbreviated laparotomy: a 17-year experience. *J Am Coll Surg*. 2014;218:636–641.
7. Ahern DP, Kelly ME, Courtney D, Rausa E, Winter DC. The management of penetrating rectal and anal trauma: a systematic review. *Injury*. 2017;48:1133–1138.
8. Bosarge PL, Como JJ, Fox N, et al. Management of penetrating extraperitoneal rectal injuries: an Eastern Association for the Surgery of Trauma practice management guideline. *J Trauma Acute Care Surg*. 2016;80:546–551.
9. Serra-Aracil X, Gómez-Díaz CJ, Navarro-Soto S, Hidalgo-Rosas JM, Mora-López L. Repair of rectal trauma perforation using transanal endoscopic operation. *Colorectal Dis*. 2012;14:e427–e428.
10. Gonzalez RP, Falimirski ME, Holevar MR. The role of presacral drainage in the management of penetrating rectal injuries. *J Trauma*. 1998;45:656–661.
11. Glasgow SC, Heafner TA, Watson JD, Aden JK, Perry WB. Initial management and outcome of modern battlefield anal trauma. *Dis Colon Rectum*. 2014;57:1012–1018.
12. Engel AF, Kamm MA, Hawley PR. Civilian and war injuries of the perineum and anal sphincters. *Br J Surg*. 1994;81:1069–1073.