

## Differentiating Shoulder Pathology from Cervical Spine Pathology: An Algorithmic Approach

Christopher M. Brusalis, MD

Karan S. Patel, MD

Howard S. An, MD

Nikhil N. Verma, MD 

From the Division of Sports Medicine and Shoulder Surgery, Hospital for Special Surgery, New York, NY (Dr. Brusalis), the Division of Spine Surgery (Dr. Patel and Dr. An), and the Division of Sports Medicine (Dr. Verma), Midwest Orthopaedics at Rush, Rush University Medical Center, Chicago, IL.

Dr. Verma or an immediate family member has received royalties from Vindico Medical-Orthopedics Hyperguide; serves as a paid consultant to Arthrex, Inc and Stryker; has stock or stock options held in Ossur; has received research or institutional support from Breg, Omeros, SLACK Incorporated, Stryker; has received nonincome support (such as equipment or services), commercially derived honoraria, or other non-research-related funding (such as paid travel) from Wright Medical Technology, Inc; Editorial or governing board; Smith & Nephew. Dr. An or an immediate family member has received royalties from U & I Inc and Zimmer; serves as a paid consultant to Dio Medical Inc and Bioventis Inc; has stock or stock options held in Articular Engineering LLC and Medyssey Inc. has received research or institutional support from Spinalcyte Inc. Spine: Editorial or governing board. Neither of the following authors nor any immediate family member has received anything of value from or has stock or stock options held in a commercial company or institution related directly or indirectly to the subject of this article: Dr. Brusalis and Dr. Patel.

*J Am Acad Orthop Surg* 2024;32:e251-e261

DOI: 10.5435/JAAOS-D-23-00210

Copyright 2023 by the American Academy of Orthopaedic Surgeons.

### ABSTRACT

Accurate and timely diagnosis of musculoskeletal conditions is an essential component of high-quality orthopaedic care. The proximity of the shoulder to the cervical spine leads to a multitude of pathologic conditions whose clinical presentations overlap, posing a diagnostic challenge to orthopaedic providers. Missed or delayed diagnosis of the etiology for patient-described ‘shoulder pain’ causes frustration among patients, incurs increased healthcare costs, and delays treatment. Moreover, patients with concurrent conditions of the cervical spine and shoulder require deliberate consideration for how each condition contributes to patients’ symptoms. The purpose of this review was to describe a systematic approach for evaluating and differentiating pathologies of the shoulder and cervical spine.

**S**houlder and neck-related pain represent two of the three leading causes of seeking musculoskeletal care in the United States.<sup>1</sup> Analogous to the relationship between the hip and the lumbar spine, the shoulder girdle and cervical spine are not merely adjacent anatomically, but share interdependent function. Nerve roots emanating from C4-C6 levels innervate the rotator cuff, periscapular stabilizing muscles, and deltoid; they also provide sensation to the skin overlying the shoulder. Consequently, pathologic conditions of the cervical spine may manifest as shoulder pain and vice versa.<sup>2</sup> This crossover phenomenon of ‘referred pain,’ in which a patient’s report of neck or shoulder pain is attributed to the incorrect anatomic site, has been estimated to occur once in every 25 patients.<sup>2</sup> Moreover, concurrent pathology at each anatomic site may act synergistically to exacerbate patient symptoms.<sup>3</sup> Parsing out the etiology of shoulder and neck conditions is a frequent, yet challenging task. In this review, we describe a systematic approach for evaluating and differentiating pathologies of the shoulder and cervical spine.

### Clinical History

A patient’s clinical history provides the highest yield data for discerning between shoulder and cervical spine conditions. A comprehensive patient

history must elucidate the location, character, severity, and chronicity of symptoms, as well as aggravating and alleviating factors. The presence of antecedent trauma, as well as the specific mechanism of injury, should be ascertained. Open-ended questions, such as ‘How would you describe your pain?’ are preferable to questions such as ‘Does your pain radiate down your arm?’ because the latter may bias patient towards a positive answer. Pain drawings, in which patients draw where they feel pain on a body map, can aid in characterizing the patient’s pain location and distribution.<sup>4</sup> The interviewer must obtain a thorough history of prior treatments, as well as patients’ responses to treatment. Patients with concomitant shoulder and neck conditions may have a more extensive history of medical workup because of the diagnostic challenge associated with their dual pathologies. When possible, patients with prior shoulder and/or cervical spine surgery should provide prior imaging studies, surgical reports, and arthroscopic photographs for review.

Several pain characteristics may favor either a shoulder or spine-related etiology.<sup>5</sup> While each clinical presentation requires an evaluation tailored to the unique circumstances of a particular patient, the authors propose a clinical algorithm to delineate between shoulder and spine-related pathologies (Figure 1). Posterior shoulder pain and pain that encompasses the neck region and radiates either to the medial scapula or distal to the ipsilateral elbow suggests a cervical spine pathology. Conversely, pain in the anterior aspect of the shoulder is common with biceps-related disorders, and pain over the anterolateral aspect of the shoulder is most commonly attributable to rotator cuff pathology.<sup>6</sup> Acromioclavicular joint conditions can pose a diagnostic challenge because pain often radiates into the trapezium and base of the neck on the affected side. Whereas shoulder pain is often exacerbated with overhead activities, pain associated with cervical radiculopathy may be alleviated with shoulder elevation because nerve root compression may be reduced in this position.<sup>7</sup> Night-time pain, as well as pain when laying on the affected side, also occurs commonly in several shoulder conditions.<sup>8</sup> Associated symptoms beyond pain include paresthesias, bilateral upper extremity symptoms, or difficulty with hand dexterity or balance point toward a cervical spine pathology. Symptoms that correspond to a specific dermatomal or myotomal pattern can indicate nerve root involvement and cervical spine pathology. For example, C5 radiculopathy can be associated with deltoid weakness, which can affect the muscular balance around the shoulder and may even

aggravate the symptoms of shoulder impingement. Anatomic variations among patients and overlapping innervations, however, can make correlating a patient’s symptoms with a specific nerve root challenging.<sup>9</sup> Many patients with confirmed diagnoses of cervical radiculopathy also have referred pain around the scapula in addition to the dermatomal pain in the arm. Some studies have reported only a 54% correlation between patient-reported patterns of radicular symptoms and a standard dermatomal map.<sup>10</sup> The frequency of concurrent degenerative shoulder and spine conditions increases commensurate with patient age.<sup>8</sup>

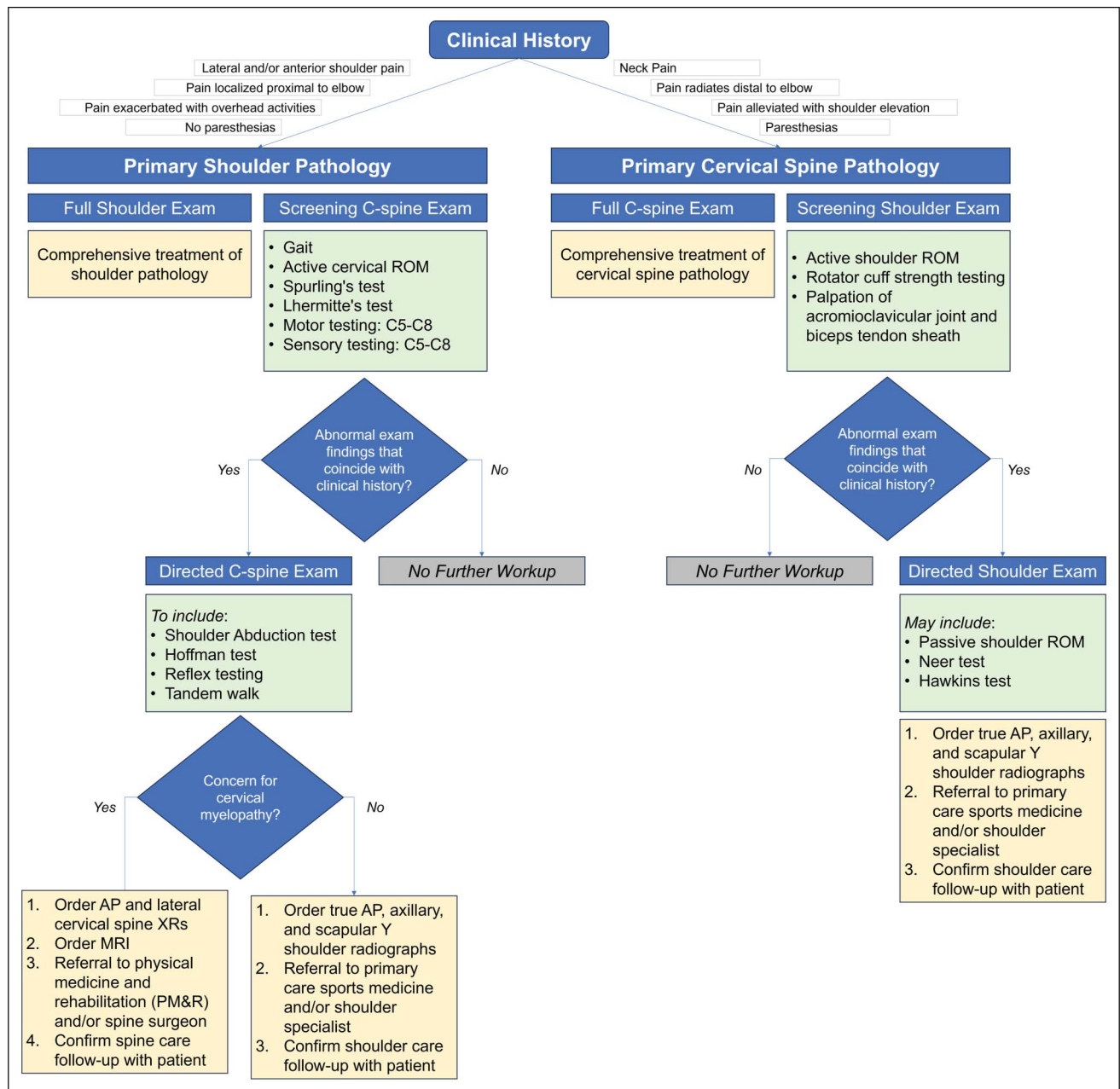
Lung-related pathologies, including lung cancers such as Pancoast tumors, can result in referred shoulder pain.<sup>11</sup> Although rare, the orthopaedic surgeon can identify and refer for treatment individuals who present with such diagnoses. If a patient, particularly one with an extensive smoking history, endorses shoulder pain exacerbated with deep inspiration, concurrent weight loss, and/or other systemic signs of illness, additional evaluation with an anterior-posterior (AP) chest radiograph and a referral to a medical provider is warranted. Moreover, an AP cervical spine radiograph may include the lung apices, which may provide an objective clue of an underlying Pancoast tumor.

## Physical Examination

The patient’s clinical history will help guide the nature of the physical examination. To reduce the risk of misdiagnosis or unrecognized concurrent pathologies, shoulder surgeons should evaluate all patients with a ‘screening’ examination of the neck while spine surgeons should evaluate all patients with a screening examination of the shoulder. In this study, we describe the recommended physical examination to conduct in each setting. A clinical algorithm for the routine evaluation of concomitant pathologies in patients with suspected shoulder or cervical spine conditions is depicted in Figure 1.

For the patient with suspected shoulder pathology, examination of the neck can usually be conducted in less than 30 seconds. The examination should begin with an assessment of the patient’s gait. Difficulty with tandem gait testing (heel-to-toe walking) or a slow, wide-based gait may be observed in patients with cervical myelopathy. The neck should then be inspected anteriorly and posteriorly for evidence of surgical scars, which may identify prior surgeries that the patient did not mention previously. Cervical range of motion should be assessed

Figure 1



Flowchart showing the clinical algorithm for the routine evaluation and diagnosis of concomitant pathologies in patients who present with a suspected shoulder or cervical spine condition.

with active neck flexion, extension, rotation, and lateral bending to each side. Pain or restricted range of motion with these maneuvers raises concern for a cervical spine condition.<sup>12</sup> Provocative maneuvers and special tests can aid in diagnosing spine pathology. A Spurling test is a commonly conducted provocative examination maneuver used to evaluate for cervical radiculopathy; however, the specific technique for conducting the test is inconsistent across clinical practice.<sup>13</sup> In our practice, the Spurling test

is conducted with the patient sitting with the neck extended, laterally flexed, and rotated toward the affected side while axial compression is applied to the patient's head, thereby compressing the cervical neural foramen. Reproduction of radiating pain and/or paresthesias to the level of the elbow or more distally indicates a positive Spurling test. Notably, despite its frequent application as a screening test, the Spurling test has shown poor sensitivity of approximately 30%, but it has shown high specificity

Downloaded from http://journals.lww.com/jaas by 169H5KCSYKMS3xg1XQuIKER82q0qUKKmZ9e1JAu16myTV/SgNZ/CPJnZAZvixU1bPpE1IBKsvBogO7nr8UvXk0Sgc8BlvPw1P6hTxxZarlHeml+cyIstDnasqA3Nob0QRrCR80EzOUB4799ekJAVE 5JbqWPVDMb0aVH80TV5yMWHQR/DyWH9FUSgy on 03/12/2024

ranging from 89 to 100%.<sup>14</sup> In addition, Lhermitte sign, in which the patient reports paresthesia in the upper or lower extremities with neck flexion, is a sign of cervical myelopathy. Neck extension or sometime manual compression of the head can produce neck pain without radicular or myelopathy signs but axial neck pain. Typically, neck extension that results in axial (ie, non-radicular) neck pain suggests pain from the facet joints or uncovertebral joints of the intervertebral disk, whereas neck flexion resulting in axial neck pain suggests myofascial pain.

Meticulous neurological examination is important including motor, sensory, and reflexes, which can help diagnose cervical radiculopathy and also the specific level of pathology (Table 1). For example, shoulder abduction strength can be diminished secondary to either rotator cuff pathology or C5 radiculopathy, but if there is decreased sensation over the C5 dermatome over the deltoid, cervical radiculopathy is the likely diagnosis.

Cervical myelopathy and diseases affecting upper motor neurons can also be assessed with special tests, such as the Hoffman test. It is performed by keeping the patient’s wrist in a relaxed extended position, stabilizing the middle finger, and flicking the distal interphalangeal joint of the middle finger. Flexion and adduction of the thumb is a positive sign, and it has been reported to have a high specificity (84%) and sensitivity (59%) for cervical myelopathy.<sup>15</sup> However, if no abnormalities are detected through the initial set of cervical spine tests, the examiner may proceed to examination of the shoulder.

For the patient with suspected cervical spine pathology without a clinical history concerning for a shoulder

condition, a brief physical examination of the shoulder may be conducted. Palpation of the shoulder should include the acromioclavicular (AC) joint and bicipital groove. Active forward elevation is assessed by asking the patient to raise his/her hand in front of their body with the elbow extended. Active external rotation with the arm at the patient’s side is assessed and compared with the contralateral arm. During examination of the shoulder, we prefer to stand behind the patient to inspect for asymmetry of scapular motion. If a limitation in active range of motion is reached, the examiner can passively guide the patient’s upper extremity to determine passive range of motion. As mentioned, pain that is exacerbated with active forward elevation or abduction is suggestive of a shoulder-based pain etiology. Additional loss of range of motion or stiffness would also suggest a shoulder condition. Supraspinatus strength testing against manual resistance is performed with the patient’s arms forward flexed 90° in the scapular plane (ie, 30° anterior to the plane of the body), with the thumbs pointed inferiorly. Asymmetric strength and/or pain with strength testing in comparison with the nonsymptomatic upper extremity suggest rotator cuff pathology. Conversely, painless weakness more commonly suggests a neurogenic etiology, including of the cervical spine.

After this ‘screening’ examination of either the neck or shoulder, a comprehensive physical examination of the more highly suspected anatomic source of a patient’s symptoms should be conducted. Specific physical examination findings pertinent for individual diagnoses are listed in Table 2.

**Table 1. Cervical Radiculopathy Patterns and Examination Guide**

Nerve Root	Symptoms	Motor Testing	Sensation Testing	Reflex
C2	Occipital headaches, temporal pain	—	—	—
C3	Occipital headaches, retroauricular pain	—	—	—
C4	Base-of-neck pain, trapezial pain	—	—	—
C5	Lateral arm pain, shoulder pain, trapezial pain	Shoulder abduction, elbow flexion	Lateral upper arm	Biceps
C6	Lateral forearm, medial scapula pain	Wrist extension, elbow flexion	Lateral forearm, thumb	Brachioradialis
C7	Medial scapula pain, posterior arm into long finger pain	Elbow extension, wrist flexion, finger extension	Long finger	Triceps
C8	Pain along medial forearm into ring and little finger	Finger flexion, hand grip	Little finger	—

## Diagnostic Tests

When evaluating a patient whose underlying condition is believed to be outside the scope of the treating surgeon's practice (ie, a patient with suspected rotator cuff tear presenting to a spine surgeon's clinic), the logistics for

how additional imaging and diagnostic tests are performed vary based on individual surgeon and group practice patterns. While some clinicians may prefer to perform their own patient evaluation before obtaining additional imaging, others may prefer that the patient obtain imaging before their referral visit. This variability

**Table 2. Common Provocative Tests for Shoulder and Cervical Spine Pathologies**

Provocative Test	Description	Positive Finding	Common Pathologies
Hawkins test	With the patient's arm in 90° of forward flexion, the examiner performs internal rotation of the shoulder with progressive adduction.	Pain at the anterior edge of the acromion	Subacromial impingement
Jobe test	With the patient's arm in 90° of forward flexion, 30° of adduction, and full internal rotation, the examiner applies a downward force on the patient's arm. Pain and/or weakness signify a positive test.	Pain and/or weakness	Supraspinatus tendinitis vs. Tear
Speed test	With the patient's arm in 90° of forward flexion, elbow in full extension, and forearm in full supination, the examiner applies a downward force on the patient's forearm.	Pain over the bicipital groove	Biceps tendinitis
O'Brien test	With the patient's arm in 90° of forward flexion, 15° of adduction, and full internal rotation (thumbs down position), the examiner applies a downward force on the patient's arm.	Pain followed by relief of pain when the same maneuver is performed with the arm supinated (thumbs up position)	Superior labral biceps complex; acromioclavicular joint
Spurling test	Patient sitting with the neck extended, laterally flexed and rotated toward the affected side while axial compression is applied to the patient's head	Pain and recreation of radicular symptoms	Cervical radiculopathy
Shoulder abduction test (Bakody sign)	Patient sitting with their affected arm abducted and hand resting on their head	Improvement in pain and radicular symptoms	Cervical radiculopathy
Hoffman sign	Patient's wrist is held in a relaxed extended position, stabilizing the middle finger, and flicking the distal interphalangeal joint of the middle finger	Flexion and adduction of the ipsilateral thumb	Cervical myelopathy
Babinski sign	Plantar stimulation by stroking the lateral aspect of the plantar foot from the heel toward the metatarsal heads	Upward movement and extension of the toes is an abnormal response	Cervical myelopathy
Finger escape sign	Patient is told to hold their fingers in full extension and adduction for a few seconds	Escape of the little finger into abduction and flexion	Cervical myelopathy

highlights the value of developing collaborative referral patterns in which colleagues of differing specialties can communicate their preferences to streamline patient care. These relationships are especially valuable for evaluating patients with challenging diagnoses and/or concurrent shoulder and cervical spine conditions.

## Imaging

When a patient presents to clinic with purported neck symptoms, but whose clinical history and physical examination suggest a primary or concomitant shoulder-related condition, it is likely that the patient has only obtained imaging related to his/her cervical spine. Therefore, the treating physician should initiate additional diagnostic evaluation by ordering shoulder radiographs, ideally obtained at the time of the clinical encounter. The initial radiographic evaluation of patients with shoulder-related complaints consists of a series of three radiographs: a Grashey or ‘true’ AP view, an axillary lateral radiograph, and a scapular-Y view. In the Grashey view, the radiograph beam is rotated medially approximately 30° to 45° to be tangential to the glenohumeral joint.<sup>16</sup> This view allows for improved visualization of abnormal findings, such as glenohumeral joint space narrowing and rotator cuff pathology, in comparison with a standard AP radiograph that is obtained orthogonally to the plane of the body.<sup>17</sup> While innumerable findings on initial radiographs may inform the shoulder specialist, we recommend that the referring provider be familiar with four ‘high-yield’ abnormalities (Figure 2). Glenohumeral osteoarthritis is suggested by (1) joint space narrowing on the true AP and axillary lateral radiographs, (2) an inferior humeral head osteophyte, and (3) posterior subluxation of the humeral head on an axillary lateral radiograph. Superior migration of the humeral head, or a decrease in the acromiohumeral interval, on a true AP radiograph is suggestive of a chronically deficient rotator cuff, termed ‘rotator cuff arthropathy.’ However, all imaging studies must be interpreted with clinical context because they will often demonstrate degenerative changes or abnormal findings which may or may not be clinically relevant. Correlation between imaging findings with patient history and physical examination is imperative in reaching a diagnostic conclusion.

In clinical practices in which an orthopaedic surgeon treats both shoulder and spine conditions, the treating surgeon may consider ordering a magnetic resonance imaging (MRI) study without contrast in cases of suspected rotator cuff dysfunction. Note that if the patient is referred to a specialist outside of the referring surgeon’s

practice, the referral surgeon may prefer to (1) evaluate the patient before ordering an MRI and/or (2) have the patient undergo an MRI within the treating surgeon’s practice, facilitating access to imaging and communication with intradepartmental radiologists.

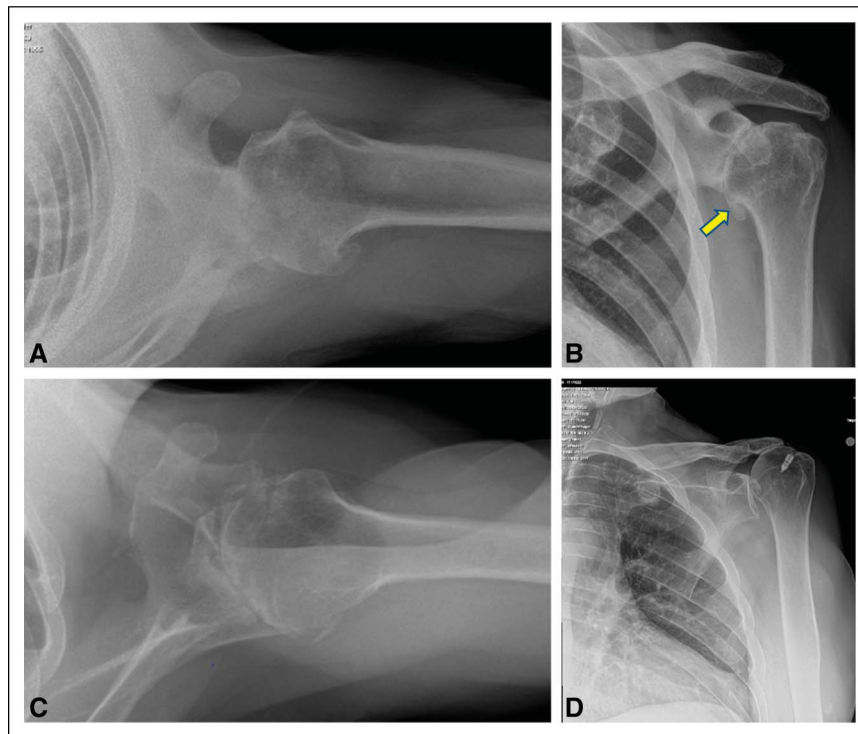
When a patient’s clinical history and physical examination suggest an underlying cervical spine condition, radiographic imaging should be ordered routinely and, ideally, at the time of the initial clinical encounter for immediate review. The initial radiographic evaluation of patients with cervical spine-related concerns consists of obtaining orthogonal radiographs in the form of AP and lateral views. The AP view can allow disk height, coronal alignment, and uncovertebral joints to be assessed. The lateral view allows disk height, facet joints, and sagittal alignment to be readily assessed.<sup>18</sup> Special views such as oblique views can help better visualize the neural foramen. Flexion and extension views can help assess for instability and spondylolisthesis while the open-mouth view (odontoid view) can allow the upper cervical spine and C1-C2 articulations to be evaluated.<sup>19</sup> Characteristics of degenerative spondylotic disease such as loss of disk height, end plate sclerosis, osteophyte formation, loss of cervical lordosis and alignment, and facet arthrosis can be identified on radiographs before obtaining advanced imaging.

Similar to shoulder-related pathologies, MRI without contrast is the imaging modality of choice for cervical spine pathology. It allows for the evaluation of bone and soft-tissue structures including the spinal cord, nerves, and intervertebral disks. It can make evaluation of disk herniation, nerve root of spinal cord compression, possible and can help identify which levels within the cervical spine are affected.<sup>19</sup> When referring a patient to a spine specialist, the authors recommend ordering a cervical spine MRI without contrast in cases of suspected cervical myelopathy to facilitate timely diagnosis and treatment. In patients with predominantly axial neck pain, ordering a cervical spine MRI may be left to the discretion of the spine specialist.

## Diagnostic Injections

In patients whose clinical presentation remains difficult to decipher, local corticosteroid injections offers both potential symptomatic relief for patients and diagnostic information for providers. Symptomatic improvement after administration of a corticosteroid injection suggests that the injected anatomic site is a significant mediator of patient symptoms. Within the shoulder complex, corticosteroid injections may be localized to the subacromial space, glenohumeral joint, acromioclavicular joint, and bicipital groove.<sup>20</sup> While multiple formulations exist, in our

Figure 2



Examples of five common abnormal findings identified on initial shoulder radiographs. Glenohumeral osteoarthritis is indicated by joint space narrowing on the axillary lateral radiograph (A) and the presence of an osteophyte on the inferior humeral head (arrow) (B). In more advanced cases of glenohumeral osteoarthritis, posterior subluxation of the humeral head relative to the glenoid can be seen (C). Superior migration of the humeral head indicates chronic rotator cuff insufficiency (D).

practice, a diagnostic injection into the subacromial space or glenohumeral joint consists of 4 mL of 2% lidocaine, 4 mL of 0.5% bupivacaine, and 2 mL of 40 mg/mL methylprednisolone. For injections into the acromioclavicular joint or biceps tendon sheath, a 3-mL solution consisting of a 1:1:1 mixture of the aforementioned substances is used.

Three factors are critical to maximize the diagnostic yield of corticosteroid injections. First, use of ultrasonography guidance to administer corticosteroids improves the accuracy of injections as compared with the use of anatomic landmarks, ensuring that patients' clinical responses are accurate reflections of the effect of corticosteroids.<sup>21</sup> Second, simultaneous corticosteroid injections of multiple anatomic locations should be avoided because this diminishes their diagnostic utility. Each corticosteroid injection should be followed by a period of observation to monitor for a patient's response. Despite an understandable interest in providing patients with immediate symptom relief, it must be recognized that patients have often been living with their conditions chronically. With appropriate patient education and provider patience, corticosteroid in-

jections may be performed sequentially, beginning with the anatomic area most likely to be the source of patient symptoms. Third, at the time of corticosteroid administration, patients must be instructed to monitor for a change in their symptoms over subsequent weeks. Without proactive directions, patients may have difficulty recalling whether their symptoms improved, for how long, and to what extent after a corticosteroid injection. A patient diary may be an effective means for patients to capture their symptoms and avoid recall bias (Table 3).<sup>22</sup>

Injections can be used in the cervical spine for diagnostic and therapeutic purposes. Epidural steroid injections can be used to provide pain relief in patients with cervical radiculopathy. Selective nerve root injections (SNIs) are a diagnostic modality which involves the injection of a small amount of local anesthetic around a nerve root in the cervical neural foramen.<sup>23</sup> They are used to identify affected nerve roots and spinal levels in cases of cervical radiculopathy. A study of 101 patients with cervical or lumbar pathology who underwent preoperative SNI reported that 91% of patients who experienced pain and symptomatic relief after a SNI

**Table 3. Diagnostic Pearls for Identifying Concomitant Shoulder and Cervical Spine Pathologies**

Evaluation	Pearls
Clinical history	<ul style="list-style-type: none"> <li>• Ask open-ended questions to avoid biasing patient responses</li> <li>• Instruct patient to complete a pain drawing before clinical encounter</li> </ul>
Physical examination	<ul style="list-style-type: none"> <li>• Perform a brief screening examination of the cervical spine in all patients presenting with self-reported shoulder pain, and vice versa</li> </ul>
Imaging	<ul style="list-style-type: none"> <li>• Order a Grashey, or ‘true’ anterior-posterior view, in the standard shoulder radiograph series</li> </ul>
Diagnostic injections	<ul style="list-style-type: none"> <li>• At the time of injection, instruct patients to take a diary of symptoms over the ensuing weeks to improve patient recall at a subsequent clinic visit. Inquire to determine whether injection at one anatomic site provided relief at adjacent sites</li> </ul>

had a successful postoperative result with regard to Visual Analog Scale (VAS) scores and patient-reported satisfaction.<sup>23</sup> These findings suggest that SNIs can be successfully used preoperatively to localize symptomatic levels that can benefit from surgical intervention.

### Electrodiagnostic Studies

Electrodiagnostic studies consist of two main components, nerve conduction studies and electromyography (EMG).<sup>24</sup> These studies allow the peripheral nervous system to be assessed and can be used to localize pathology at various levels including the cervical nerve roots, brachial plexus, peripheral nerves, neuromuscular junction, and muscles.<sup>24</sup> Nerve conduction studies stimulate peripheral nerves and analyze distal latency, conduction velocity, and amplitude. EMG analyzes resting muscle activity and motor unit action potentials on stimulation.<sup>24</sup> These studies can identify peripheral versus central causes of radiculopathy and can also be used to differentiate between motor neuron diseases that may produce a clinical picture similar to radiculopathy.<sup>19</sup>

### Differential Diagnosis

In this section, we highlight diagnostic pearls for specific conditions whose clinical presentations overlap or masquerade as shoulder and/or cervical spine pathology.

### Shoulder Conditions

#### Suprascapular Neuropathy

Injury to the suprascapular nerve, which innervates the supraspinatus and infraspinatus muscles, most commonly occurs at either the suprascapular notch or the spinoglenoid notch. When compressed at the level of the suprascapular notch, weakness and/or atrophy of both the supraspinatus and infraspinatus may be seen. Con-

versely, if the compression and/or injury occurs at the spinoglenoid notch, which is distal to the branching innervation of the supraspinatus, isolated weakness and/or muscular atrophy of the infraspinatus may be evident. Patients may report posterior shoulder pain that radiates into the neck region. On examination, frank atrophy of the supraspinatus and/or infraspinatus is often visible. Sagittal T1 MRI images may demonstrate atrophy of the supraspinatus and/or infraspinatus musculature, most commonly without fatty infiltration. In addition, neurogenic myopathy signal may be present on T2 imaging. Electrodiagnostic studies often confirm the diagnosis by revealing abnormalities in nerve conduction velocity.

#### Brachial Neuritis (Parsonage-Turner Syndrome)

Brachial neuritis is a rare condition whose clinical presentation often involves an atraumatic, acute onset of sharp and severe shoulder pain that may last from hours to weeks. As pain diminishes, an onset of flaccid paralysis of the shoulder girdle ensues, most commonly within 2 weeks of the initial onset of pain symptoms.<sup>25</sup> Clinical presentation is quite variable, and sites of pain and/or weakness can occur in a patchy distribution which transcend dermatomes. The temporal sequence of pain followed by weakness is distinct from the more common diagnosis of cervical radiculopathy, in which pain and weakness typically occur simultaneously. Recently, MRI has been shown to identify alterations in the nerve structure, including hourglass-like constrictions and torsion, which can more reliably diagnose brachial neuritis.<sup>26</sup> EMG can also help distinguish brachial neuritis. Whereas acute denervation is typically confined to a single nerve root in cervical radiculopathy, brachial neuritis often demonstrates evidence of acute denervation across both nerve roots and peripheral nerves.<sup>27</sup>

Downloaded from http://journals.lww.com/jaas by 169H5KCSYK/M53xqtlXQuIK822q0qUKKmZ9cflJAJl6myTV/SgnZ/CPJrtAZAvyXUlbPe1IBKsvBogQrny8UvXkSoScB1VPlwTjP6tTxxZetHeml+cyIsDnasqA3NobQRCR80EZOUJ84799ekJAVE5JbqWPVDmB0aVH80TV5yMhQR/DyWH9FUSgy on 03/12/2024



## Thoracic outlet syndrome

Thoracic outlet syndrome (TOS) is a rare condition that occurs secondary to neurovascular plexus compression at the thoracic outlet, leading to a constellation of symptoms including arm pain, weakness, paresthesias, and/or hand swelling.<sup>28</sup> While multiple subtypes exist, brachial plexus compression results in neurogenic TOS. Owing to its nonspecific symptoms, neurogenic TOS can be especially challenging to diagnose.<sup>29</sup> Two adjunctive provocative examination tests aid in diagnosis. In the elevated arm stress test, the patient lays supine, positions their shoulder in 90° abduction and 90° external rotation, and performs repetitive hand opening and closing. Pain or neurologic disturbances that reproduce the patient's presenting concerns are considered a positive test.<sup>30</sup> In the upper limb tension test, the patient's arm is positioned in 90° abduction and 90° external rotation, the elbow is fully extended, the forearm is pronated, and the wrist is flexed. This position places the brachial plexus on maximal stretch, and a positive test is indicated by the presence of pain and/or neurologic dysfunction.<sup>31</sup>

## Cervical Spine Conditions

### Cervical Radiculopathy

Cervical radiculopathy is characterized by nerve root dysfunction as they exit the spinal cord in the cervical spine. These can result from spondylotic changes such as disk degeneration that narrow the neural foramen and osteophyte formation from facet and uncovertebral joints.<sup>32</sup> While patients may typically present with arm pain and sensory and motor dysfunction in a specific dermatomal and myotomal pattern, patient presentations can vary significantly.<sup>32</sup>

Patients with C2 and C3 nerve root pathology will typically present with occipital headaches and do not refer pain to the shoulder (Table 1).<sup>6,32,33</sup> C4 nerve root pathology occurs as the nerve exits the C3-C4 foramen and can present typically with pain rather than sensory or motor disturbances. The C4 dermatome extends from the dorsal and lateral neck medially, clavicle anteriorly, acromion laterally, and trapezius posteriorly.<sup>6</sup> The C5 nerve root exits at the C4-C5 foramen. This nerve root provides sensation to the trapezius and proximal scapula posteriorly and its dermatome extends along the neck to the deltoid and lateral arm. It can also innervate the anterior aspect of the arm above the elbow.<sup>32,33</sup> C5 radiculopathy can present with weakness in shoulder abduction and elbow flexion and diminished biceps reflex. The C6 nerve root exits at the C5-C6 foramen

and has a dermatomal pattern that typically innervates the thumb, index finger, and radial aspect of the hand. The C6 nerve root also provides motor innervation to the biceps and wrist extensors. The C7 nerve root exits at the C6-C7 foramen, provides sensory innervation to the long finger, and provides motor innervation to the triceps and wrist flexors. Rare, but existing aberrant innervations of either the C6 or C7 nerve root can, in the case of nerve root compression, result in pain along the medial border of the scapula, thus mimicking scapular and shoulder pathology. Conversely, C8 and T1 nerve root pathology will typically involve ulnar forearm and ulnar digit symptoms.

### Cervical Myelopathy

Cervical myelopathy is characterized by spinal cord compression and impairment that results in episodic worsening of symptoms with long stable periods.<sup>34</sup> Upper motor neuron symptoms such as hyperreflexia, pathologic reflexes (as tested by Hoffman sign and Babinski sign), gait and balance impairment, and loss of dexterity and fine motor skills can occur.<sup>35</sup> Patients with myelopathy may report nonspecific neck or shoulder pain that often do not follow a specific radicular pattern. Their upper extremity weakness may also be more diffuse. A diagnosis of myelopathy can be differentiated from shoulder pathology by the presence of gait imbalance, impaired hand dexterity (eg, difficulty with buttoning a shirt or worsened penmanship), and hyperactive reflexes [eg, hyperactive biceps reflex (C5), brachioradialis reflex (C6), triceps reflex (C7), and/or positive Hoffman sign]. Moreover, cervical spine MRI may demonstrate myelomalacia and severe cord compression in patients with cervical myelopathy.

### Concurrent Conditions

Dual pathologic conditions of the cervical spine and shoulder occur frequently. In one study by Cannon et al,<sup>36</sup> approximately 10% of patients referred for a cervical spine condition demonstrated comorbid shoulder pathology. When dual pathologic conditions are suspected, close collaboration between treating specialists is paramount to optimize patient outcomes. Alternatively, it should be noted that the treating surgeon, particularly those in settings with a broad scope of clinical practice, may appropriately care for both conditions without referral. Decisions regarding the evaluation of such patients vary based on the suspected clinical diagnoses, patient factors, and practice environment. However, we recommend several guiding principles. First, the patient must be counseled regarding

the physicians' clinical assessment of a multifactorial etiology of symptoms. Thoughtful discussion with the patient can help derive which constellation of symptoms, from either the shoulder or cervical spine, make a more substantial contribution to the patient's symptoms. Second, the primary treatment team for each condition should communicate directly regarding the patient's evaluation and subsequent management. Patients' comprehension and knowledge retention from communications with medical providers is unreliable.<sup>37-39</sup> Patients should not, therefore, serve as intermediaries for conveying critical health information between collaborating specialty physicians. Spine surgeons, sports medicine and shoulder surgeons, and physical medicine and rehabilitation physicians may communicate using a shared electronic medical record system, an encrypted e-mail messaging system, or through telephone or in-person conversation to strategize ongoing care. Third, after initial diagnostic and therapeutic interventions, such as pain medications, formal physical rehabilitation, and corticosteroid injections, patients should be queried for improvement in symptoms at all anatomic sites. Symptomatic relief across the neck, shoulder, and arm after a targeted diagnostic injection may suggest that multiple surgical interventions to treat different conditions may be unnecessary. Moreover, a substantial, albeit poorly quantified proportion of patients with concomitant pathologies experience durable relief of one or both conditions through a comprehensive nonsurgical treatment approach. This clinical finding underscores the value of the initial treating surgeon caring for both of the patient's conditions or referring to a colleague in primary care sports medicine and/or physical medicine and rehabilitation, as dictated by the initial surgeon's clinical assessment.

In patients with concurrent conditions of the shoulder and cervical spine in which surgery is indicated for both pathologies, patients will commonly ask, 'Which condition should we treat first?' The available evidence to evaluate the preferred sequence of surgical treatment is relatively scant. D'Antonio et al<sup>40</sup> compared 44 patients who underwent anterior cervical discectomy and fusion (ACDF) followed by rotator cuff surgery with an analogous cohort of 41 patients who underwent both procedures in the reverse sequence. No differences in postoperative patient-reported outcome measures or surgical revision rates were detected. In general, we recommend that surgical interventions to treat progressive neurologic disorders, such as cervical myelopathy, be prioritized over surgical interventions of the

shoulder. In the absence of such a condition, the collaborating surgeons and patient must communicate to determine and intervene on the condition providing a more notable effect on the patient's quality of life. Moreover, an adequate postoperative recovery period must be allotted to determine whether treatment of one condition alleviates the symptoms from the suspected condition at another anatomic site. High-quality evidence is needed to elucidate the optimal sequence of surgical intervention in various conditions of dual shoulder and cervical spine pathology.

## Summary

In patients with suspected shoulder and/or cervical spine pathology, a systematic patient evaluation of clinical history, physical examination, and imaging studies enables the physician to delineate between overlapping clinical symptoms, as well as identify cases of concurrent pathology. Selective diagnostic corticosteroid injections, with careful attention to patient response, aid in identifying a hierarchy of patient pathologies. Treatment of one primary condition of the neck or shoulder may resolve related, secondary symptoms. Collaboration between multiple treatment providers streamlines the diagnostic workup and avoids unnecessary treatments to optimize patient care.

## References

1. Fish DE, Gerstman BA, Lin V: Evaluation of the patient with neck versus shoulder pain. *Phys Med Rehabil Clin N Am* 2011;22:395-410.
2. Sembrano JN, Yson SC, Kanu OC, et al: Neck-shoulder crossover: How often do neck and shoulder pathology masquerade as each other?. *Am J Orthop* 2013;42:E76-E80.
3. Katsuura Y, Yao K, Chang E, Kadrie TA, Dorizas JA: Shoulder double crush syndrome: A retrospective study of patients with concomitant suprascapular neuropathy and cervical radiculopathy. *Clin Med Insights Arthritis Musculoskelet Disord* 2020;13:1179544120921854.
4. Kanellopoulos AK, Kanellopoulos EK, Dimitriadis Z, et al: Novel software for pain drawing analysis. *Cureus* 2021;13:e20422.
5. Ponnappan RK, Khan M, Matzon JL, et al: Clinical differentiation of upper extremity pain etiologies. *J Am Acad Orthop Surg* 2015;23:492-500.
6. Throckmorton TQ, Kraemer P, Kuhn JE, Sasso RC: Differentiating cervical spine and shoulder pathology: Common disorders and key points of evaluation and treatment. *Instr Course Lect* 2014;63:401-408.
7. Bokshan SL, DePasse JM, Eltorai AEM, Paxton ES, Green A, Daniels AH: An evidence-based approach to differentiating the cause of shoulder and cervical spine pain. *Am J Med* 2016;129:913-918.
8. Pateder DB, Berg JH, Thal R: Neck and shoulder pain: Differentiating cervical spine pathology from shoulder pathology. *J Surg Orthop Adv* 2009;18:170-174.
9. Riew KD: Variations in cervical myotomes and dermatomes. *Spine J* 2019;19:1143-1145.

10. McAnany SJ, Rhee JM, Baird EO, et al: Arceo, R: Observed patterns of cervical radiculopathy: How often do they differ from a standard, "netter diagram" distribution?. *Spine J* 2019;19:1137-1142.
11. Al Shammari M, Hassan A, Al Jawad M, et al: Pancoast tumor: The overlooked etiology of shoulder pain in smokers. *Am J Case Rep* 2020;21:e926643.
12. Walker T, Cuff A, Salt E, Lynch G, Littlewood C: Examination of the neck when a patient complains of shoulder pain: A global survey of current practice (2019). *Musculoskeletal Care* 2020;18:256-264.
13. Jinright H, Kassoff N, Williams C, Hazle C: Spurling's test - inconsistencies in clinical practice. *J Man Manip Ther* 2021;29:23-32.
14. Tong HC, Haig AJ, Yamakawa K: The Spurling test and cervical radiculopathy. *Spine* 2002;27:156-159.
15. Haddas R, Cox J, Belanger T, Ju KL, Derman PB: Characterizing gait abnormalities in patients with cervical spondylotic myelopathy: A neuromuscular analysis. *Spine J* 2019;19:1803-1808.
16. Sanders TG, Jersey SL: Conventional radiography of the shoulder. *Semin Roentgenol* 2005;40:207-222.
17. Koh KH, Han KY, Yoon YC, Lee SW, Yoo JC: True anteroposterior (Grashey) view as a screening radiograph for further imaging study in rotator cuff tear. *J Shoulder Elbow Surg* 2013;22:901-907.
18. Tao Y, Galbusera F, Niemeyer F, Samartzis D, Vogele D, Wilke HJ: Radiographic cervical spine degenerative findings: A study on a large population from age 18 to 97 years. *Eur Spine J* 2021;30:431-443.
19. Kim GU, Chang MC, Kim TU, Lee GW: Diagnostic modality in spine disease: A review. *Asian Spine J* 2020;14:910-920.
20. Naunton J, Harrison C, Britt H, Haines T, Malliaras P: General practice management of rotator cuff related shoulder pain: A reliance on ultrasound and injection guided care. *PLoS One* 2020;15:e0227688.
21. Yiannakopoulos CK, Megaloiakonimos PD, Foufa K, Gliatis J: Ultrasound-guided versus palpation-guided corticosteroid injections for tendinosis of the long head of the biceps: A randomized comparative study. *Skeletal Radiol* 2020;49:585-591.
22. Sonnabend DH: Patient diary helps assessment. *J Shoulder Elbow Surg* 1994;3:346.
23. Sasso RC, Macadaeg K, Nordmann D, Smith M: Selective nerve root injections can predict surgical outcome for lumbar and cervical radiculopathy: Comparison to magnetic resonance imaging. *J Spinal Disord Tech* 2005;18:471-478.
24. Davenport R, Jandzinski M, Ahmed M, Stino A, Aleem I: Electrodiagnostic studies in degenerative cervical myelopathy. *Clin Spine Surg* 2022;35:403-409.
25. Tjounmakaris FP, Anakwenze OA, Kancherla V, Pulos N: Neuralgic amyotrophy (Parsonage-Turner syndrome). *J Am Acad Orthop Surg* 2012;20:443-449.
26. Gstoettner C, Mayer JA, Rassam S, et al: Neuralgic amyotrophy: A paradigm shift in diagnosis and treatment. *J Neural Neurosurg Psychiatry* 2020;91:879-888.
27. Silverman B, Shah T, Bajaj G, Hodde M, Popescu A: The importance of differentiating parsonage-turner syndrome from cervical radiculopathy: A case report. *Cureus* 2022;14:e28723.
28. Panther EJ, Reintgen CD, Cueto RJ, Hao KA, Chim H, King JJ: Thoracic outlet syndrome: A review. *J Shoulder Elbow Surg* 2022;31:e545-e561.
29. Dengler NF, Ferraresi S, Rochkind S, et al: Thoracic outlet syndrome Part I: Systematic review of the literature and consensus on anatomy, diagnosis, and classification of thoracic outlet syndrome by the European association of neurosurgical societies' section of peripheral nerve surgery. *Neurosurgery* 2022;90:653-667.
30. Sanders RJ, Hammond SL, Rao NM: Diagnosis of thoracic outlet syndrome. *J Vasc Surg* 2007;46:601-604.
31. Panda N, Donahue DM: Evaluation of patients with neurogenic thoracic outlet syndrome. *Thorac Surg Clin* 2021;31:55-59.
32. Woods BI, Hillbrand AS: Cervical radiculopathy: Epidemiology, etiology, diagnosis, and treatment. *J Spinal Disord Tech* 2015;28:E251-E259.
33. Rhee JM, Yoon T, Riew KD: Cervical radiculopathy. *J Am Acad Orthop Surg* 2007;15:486-494.
34. Nouri A, Tetreault L, Singh A, Karadimas SK, Fehlings MG: Degenerative cervical myelopathy: Epidemiology, genetics, and pathogenesis. *Spine* 2015;40:E675-E693.
35. Iyer A, Azad TD, Tharin S: Cervical spondylotic myelopathy. *Clin Spine Surg* 2016;29:408-414.
36. Cannon DE, Dillingham TR, Miao H, Andary MT, Pezzini LE: Musculoskeletal disorders in referrals for suspected cervical radiculopathy. *Arch Phys Med Rehabil* 2007;88:1256-1259.
37. Crepeau AE, McKinney BI, Fox-Ryvicker M, Castelli J, Penna J, Wang ED: Prospective evaluation of patient comprehension of informed consent. *J Bone Joint Surg Am* 2011;93:e1141.
38. Rossi MJ, Brand JC, Provencher MT, Lubowitz JH: The expectation game: Patient comprehension is a determinant of outcome. *Arthroscopy* 2015;31:2283-2284.
39. Cosic F, Kimmel L, Edwards E: Patient comprehension of common orthopedic terminology. *Health Lit Res Pract* 2019;3:e187-e193.
40. D'Antonio ND, Lambrechts MJ, Levy HA, et al: Patients with dual shoulder-spine disease: Does operative order affect clinical outcomes?. *World Neurosurg* 2022;164:e1269-e1280.